

Chapter 02: Chest

Lampignano: Bontrager's Textbook of Radiographic Positioning and Related Anatomy, 9th Edition

MULTIPLE CHOICE

1. The two most common landmarks for chest positioning are the:
 - a. top of shoulders and xiphoid process.
 - b. jugular notch and top of shoulders.
 - c. lower margin of thyroid cartilage and vertebra prominens.
 - d. jugular notch and vertebra prominens.

ANS: D

REF: 72

2. The vertebra prominens corresponds to the level of:
 - a. C7.
 - b. C5.
 - c. T2.
 - d. C4-5.

ANS: A

REF: 72

3. The upper margin of the lungs is at the level of the:
 - a. jugular notch.
 - b. vertebra prominens.
 - c. laryngeal prominence.
 - d. sternal angle.

ANS: B

REF: 72

4. What is the name of the structure that serves as a common passageway for both food and air?
 - a. Epiglottis
 - b. Larynx
 - c. Pharynx
 - d. Esophagus

ANS: C

REF: 73

5. The jugular notch is located on the:
 - a. sternum.
 - b. thyroid cartilage.
 - c. seventh cervical vertebra.
 - d. scapula.

ANS: D

REF: 72

6. What is the correct anatomic name for the Adam's apple?
 - a. Sternum
 - b. Epiglottis
 - c. Cricoid cartilage
 - d. Laryngeal prominence

ANS: D

REF: 74

7. What is the name for the structure that serves as a lid over the larynx to prevent aspiration of food or fluid?
- Uvula
 - Epiglottis
 - Hyoid bone
 - Oropharynx

ANS: B

REF: 74

8. Which of the following structures is considered to be most posterior?
- Larynx
 - Esophagus
 - Trachea
 - Hyoid bone

ANS: B

REF: 75

9. The lower concave area of the lung is termed the:
- base.
 - apex.
 - hilum.
 - costophrenic angle.

ANS: A

REF: 77

10. Which of the following structures is considered to be most inferior?
- Epiglottis
 - Hyoid bone
 - Carina
 - Vocal cords

ANS: C

REF: 77

11. The internal prominence or ridge in which the trachea bifurcates into the right and left bronchi is termed the:
- carina.
 - hilum.
 - thyroid cartilage.
 - costophrenic angle.

ANS: A

REF: 76

12. The inner layer of the pleura that encloses the lungs and heart is called the:
- parietal pleura.
 - pericardial sac.
 - pulmonary or visceral pleura.
 - omentum.

ANS: C

REF: 77

13. Air or gas that escapes from the lungs into the pleural cavity results in a condition known as:
- air bronchogram.
 - pneumothorax.
 - hemidiaphragm.
 - hemothorax.

ANS: B

REF: 76

14. Which of the following structures is NOT considered as a mediastinal structure?
- Thymus gland
 - Aorta
 - Trachea
 - Epiglottis

ANS: D

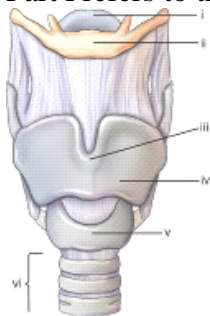
REF: 79

15. The laryngeal prominence is a positioning landmark located at the level of:
- T1.
 - C7.
 - C5.
 - C3.

ANS: C

REF: 74

16. Part **i** refers to the:

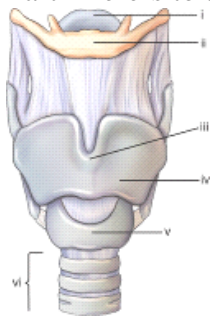


- hyoid bone.
- larynx.
- laryngeal prominence.
- epiglottis.

ANS: D

REF: 74

17. Part **ii** refers to the:



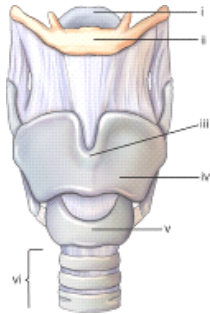
- hyoid bone.
- larynx.

- c. upper thyroid cartilage.
- d. upper border of trachea.

ANS: A

REF: 74

18. Part **iii** refers to the:

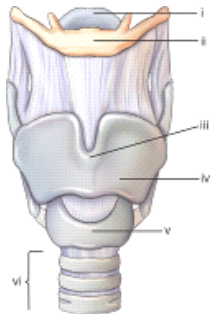


- a. thyroid cartilage.
- b. carina.
- c. laryngeal prominence.
- d. hyoid bone.

ANS: C

REF: 74

19. Part **iv** refers to the:

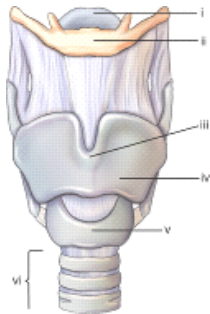


- a. laryngeal prominence.
- b. carina.
- c. thyroid cartilage.
- d. cricoid cartilage.

ANS: C

REF: 74

20. Part **v** refers to the:

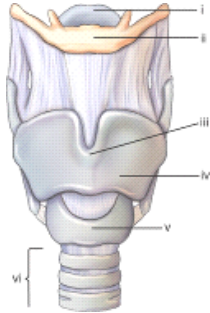


- a. trachea.
- b. larynx.
- c. thyroid cartilage.
- d. cricoid cartilage.

ANS: D

REF: 74

21. Part **vi** refers to the:



- a. trachea.
- b. larynx.
- c. thyroid cartilage.
- d. esophagus.

ANS: A

REF: 74

22. The thyroid gland is located at the approximate level of:

- a. C1-3.
- b. the carina.
- c. the epiglottis.
- d. C5-7.

ANS: D

REF: 75

23. The thymus gland is at its maximum size at:

- a. age 40.
- b. age 21.
- c. puberty.
- d. birth.

ANS: C

REF: 75

24. The heart is located in the anterior chest at the level of:

- a. T10-12.
- b. the thymus gland.
- c. the arch of the aorta.
- d. T5-8.

ANS: D

REF: 77

25. What is a common palpable landmark for the AP chest projection on the obese patient?

- a. Xiphoid process
- b. Costal angle
- c. Jugular notch
- d. Vertebra prominens

ANS: C

REF: 87

26. The central ray (CR) for an anteroposterior (AP) supine, adult chest projection, should be centered:
- a. to the level of T4.
 - b. 3 to 4 inches (8 to 10 cm) below the jugular notch.
 - c. at the vertebra prominens.
 - d. at the xiphoid process.

ANS: B

REF: 87

27. For an AP portable chest on an older or hypersthenic male patient, which of the following should occur?
- a. The image receptor generally should be placed portrait.
 - b. The CR should be centered 3 inches (8 cm) below the jugular notch.
 - c. The CR should be centered to the mammillary (nipple) line.
 - d. None of the above should occur.

ANS: B

REF: 82 | 86

28. Which one of the following clinical indications often requires the inspiration/expiratory chest series to be taken?
- a. Chronic asthma
 - b. Small pneumothorax
 - c. Pneumoconiosis
 - d. Primary tuberculosis

ANS: B

REF: 82 | 89

29. Pleurisy may be demonstrated radiographically by associated:
- a. pleural effusion.
 - b. empyema.
 - c. pneumothorax.
 - d. silicosis.

ANS: A

REF: 90

30. What is a common radiographic sign seen on a chest radiograph for a patient with respiratory distress syndrome (RDS)?
- a. Enlargement of heart
 - b. Fluid in apices
 - c. Elevated diaphragm
 - d. Air bronchogram sign

ANS: D

REF: 89

31. Which type of body habitus typically requires that the image receptor be placed landscape rather than portrait for a posteroanterior (PA) chest?
- a. Hypersthenic
 - b. Asthenic
 - c. Sthenic
 - d. Hyposthenic

ANS: A

REF: 80

32. A general rule states that radiographic grids are required with chest radiography for:
- a. exposure factors using 80 kV or below.
 - b. exposure factors using 100 kV or greater.
 - c. all adults.
 - d. all pediatrics.

ANS: B REF: 81

33. Which of following statements is NOT true?
- a. The right lung contains three lobes.
 - b. The left bronchus is more horizontal than the right bronchus.
 - c. The right bronchus is shorter than the left bronchus.
 - d. The angle of divergence of the left bronchus is greater than that of the right bronchus.

ANS: B REF: 76

34. A well-inspired healthy adult chest PA projection will have a minimum of ____ posterior ribs seen above the diaphragm.
- a. 8
 - b. 7
 - c. 10
 - d. 12

ANS: C REF: 82

35. Which of the following objects does NOT have to be removed or moved before a chest radiography?
- a. Necklace
 - b. Bra
 - c. T-shirt
 - d. Glasses

ANS: D REF: 81

36. Which of the following analog technical factors is ideal for adult chest radiography?
- a. 100 kV, 200 mA, 1/20 seconds, 60-inch (153 cm) source image receptor distance (SID)
 - b. 120 kV, 800 mA, 1/40 seconds, 72-inch (183 cm) SID
 - c. 125 kV, 400 mA, 1/40 seconds, 40-inch (102 cm) SID
 - d. 120 kV, 600 mA, 1/60 seconds, 60-inch (153 cm) SID

ANS: B REF: 81

37. A PA chest radiograph reveals that only seven ribs are seen above the diaphragm on a healthy adult. Which of the following suggestions would improve the inspiration of lungs?
- a. Use higher kV to penetrate the diaphragm.
 - b. Perform chest position supine.
 - c. Take exposure on the second inspiration rather than on the first.
 - d. Use a shorter exposure time.

ANS: C REF: 82

38. A correctly positioned lateral chest radiograph demonstrates some separation of the posterior ribs owing to the divergent x-ray beam. But a separation of greater than ____ cm indicates objectionable rotation from a true lateral.
- 0.5
 - 2
 - 3
 - 1

ANS: D

REF: 84

39. What is the primary disadvantage of performing an AP projection of the chest rather than a PA?
- More radiation exposure to the lungs
 - Distortion of the ribs
 - AP projection requires more kV as compared with the PA projection
 - Increased magnification of the heart

ANS: D

REF: 83

40. Of the following factors, which one is most crucial to demonstrate possible air and fluid levels in the chest?
- 72-inch (183-cm) SID
 - High-kV technique
 - Patient in erect or decubitus position
 - Using high mA and short exposure time

ANS: C

REF: 83

41. A PA chest radiograph reveals that the pendulous breasts of the patient are obscuring the base of the lungs. What should be done to lessen the effects of the breast shadow?
- Ask patient to lift breasts up and outward.
 - Use a higher kV (beyond 125) to penetrate tissue.
 - Have patient take a deeper inspiration before exposure.
 - Take an AP rather than PA projection.

ANS: A

REF: 87

42. A PA chest radiograph reveals that the left sternoclavicular joint is closer to the spine than the right joint. What specific positioning error has been committed?
- Left tilt
 - Rotation into the left anterior oblique (LAO) position
 - Right tilt
 - Rotation into the right anterior oblique (RAO) position

ANS: B

REF: 92

43. Which of the following factors must be applied to minimize distortion of the heart?
- 72-inch (183-cm) SID
 - High-kV technique
 - Performing study erect
 - Using high mA and short exposure time

ANS: A

REF: 83

44. Of the following positioning actions, which one will remove most of the scapulae from the lung fields?
- Roll shoulders forward.
 - Depress shoulders.
 - Elevate chin.
 - None of the above is correct.

ANS: A

REF: 92

45. For an average-size female patient, where is the CR placed for a PA projection of the chest?
- 7 inches (18 cm) below the vertebra prominens
 - 3 inches (7.6 cm) below the jugular notch
 - 8 inches (20 cm) below the vertebra prominens
 - 2 inches (5 cm) above the shoulders

ANS: A

REF: 86

46. A condition characterized as an irreversible dilation or widening of bronchi or bronchioles that may result from repeated pulmonary infection or obstruction is termed:
- asthma.
 - bronchitis.
 - bronchiectasis.
 - dyspnea.

ANS: C

REF: 88

47. What type of CR angle is required for the AP semi axial (alternative lordotic) projection for the lung apices?
- None. CR is perpendicular to IR.
 - 10° to 15° caudad.
 - 15° to 20° cephalad.
 - 25° to 35° caudad.

ANS: C

REF: 98

48. Which chest oblique position will best demonstrate the air-filled trachea, heart, and great vessels?
- 45° RAO
 - 60° RAO
 - 45° LAO
 - 60° LAO

ANS: D

REF: 99

49. A patient enters the emergency department (ED) to be treated for severe trauma. The physician orders an AP supine chest to evaluate the lungs. What can the technologist do to reduce the magnification of the heart?
- Place the cassette landscape.
 - Use a short exposure time.
 - Increase super optical device (SOD) as much as possible.

d. Increase SID as much as possible.

ANS: D

REF: 96

50. An ambulatory patient comes to radiology with a clinical history of possible pneumonia. The patient complains of pain in the center of her chest. What positioning routine should be performed on this patient?
- a. PA and left lateral projections
 - b. PA and right and left lateral projections
 - c. PA and both decubitus projections
 - d. AP and right lateral projections

ANS: A

REF: 89

51. A patient is in the intensive care unit with multiple injuries. The attending physician is concerned about a pleural effusion in the left lung. The patient had surgery recently and cannot stand. Which position/projection would be best to rule out the pleural effusion?
- a. AP supine
 - b. Right lateral decubitus
 - c. Apical lordotic
 - d. Left lateral decubitus

ANS: D

REF: 89

52. A patient enters the ED with a possible pneumothorax in the left lung. Because of trauma, the patient cannot stand or sit erect. Which of the following positions would best demonstrate this condition?
- a. AP supine
 - b. Right lateral decubitus
 - c. Left posterior oblique (LPO) and right posterior oblique (RPO)
 - d. Left lateral decubitus

ANS: B

REF: 89

53. A patient comes to radiology for a routine chest study. On the PA projection, the radiologist sees a possible calcification near a rib, but she cannot tell whether the calcification is in the lung or on the rib. What additional projections would assist with the diagnosis?
- a. Apical lordotic
 - b. Right lateral
 - c. Inspiration/expiration PA
 - d. Both lateral decubitus

ANS: C

REF: 82

54. A patient enters the ED with a possible hemothorax in the right lung. With help, the patient can sit erect on a cart. Which of the following routines would best demonstrate this condition?
- a. Erect PA and erect right lateral on cart
 - b. Right lateral decubitus
 - c. Left lateral decubitus
 - d. RPO and LAO erect

ANS: A

REF: 97

55. A patient comes to radiology with a possible mass beneath the right clavicle. The PA and left lateral projections are inconclusive. Which additional projection/position can be taken to demonstrate this possible mass?
- a. AP erect
 - b. Right lateral
 - c. AP and lateral of upper airway
 - d. AP lordotic

ANS: D

REF: 98

56. Why must the technologist slightly angle the CR caudad for most AP projections of the chest?
- a. Elongates the carina.
 - b. Prevents overlap of the chin on the upper airway.
 - c. Separates the heart from the great vessels.
 - d. Prevents clavicles from obscuring apices of the lungs.

ANS: D

REF: 96

57. Which positioning line must be placed perpendicular to the plane of the IR for an AP projection of the upper airway?
- a. Mentomeatal
 - b. Midcoronal
 - c. Acanthiomeatal
 - d. Orbitomeatal

ANS: C

REF: 103

58. Which of the following is NOT a form of occupational lung disease?
- a. Silicosis
 - b. Tuberculosis
 - c. Anthracosis
 - d. Asbestosis

ANS: B

REF: 91

59. Which of the following is a condition in which all or part of a lung is collapsed, requiring an increase in manual exposure (analog) factors?
- a. Pneumonia
 - b. Pneumothorax
 - c. Bronchiectasis
 - d. Atelectasis

ANS: D

REF: 89

60. Situs inversus is a condition in which:
- a. the heart is located in the left thorax.
 - b. the liver is in the left abdomen.
 - c. all major organs are in the opposite side of the body.
 - d. the thymus gland is absent.

ANS: C

REF: 81

61. The CR for an AP supine chest should be aligned:

- a. perpendicular to the long axis of sternum.
- b. at the level of the jugular notch.
- c. at the level of the xiphoid process.
- d. perpendicular to the long axis of the clavicles.

ANS: A REF: 87 | 96

62. What is the recommended kV range for upper airway projections (analog and digital imaging)?
- a. 50 to 65 kV
 - b. 110 to 120 kV
 - c. 75 to 85 kV
 - d. 90 to 100 kV

ANS: C REF: 103

MATCHING

Select the exposure factor adjustments needed for the pathologic indication(s) using manual exposure settings (no AEC). Increases or decreases in manual exposure factors are compared with the ideal exposure factors that would be used on a normal, healthy individual.

- a. Increase (+)
 - b. Decrease (–)
 - c. No change (0)
1. Advanced bronchiectasis
 2. Pneumothorax
 3. Severe pulmonary edema
 4. Severe emphysema
 5. Cystic fibrosis (severe)
 6. Pneumonia
 7. Silicosis (severe)
 8. Bronchitis
 9. Epiglottitis
 10. Large pleural effusion
 11. Pleurisy
 12. Tuberculosis (primary or secondary)
 13. Advanced respiratory distress syndrome (RDS)
 14. Mild chronic obstructive pulmonary disease (COPD)
 15. Aspiration in upper airway (mechanical obstruction)
 16. Malignant lung neoplasia
 17. Pulmonary emboli

- | | |
|-----------|------------|
| 1. ANS: C | REF: 88-91 |
| 2. ANS: C | REF: 88-91 |
| 3. ANS: A | REF: 88-91 |
| 4. ANS: B | REF: 88-91 |
| 5. ANS: A | REF: 88-91 |
| 6. ANS: C | REF: 88-91 |

- | | |
|------------|------------|
| 7. ANS: C | REF: 88-91 |
| 8. ANS: C | REF: 88-91 |
| 9. ANS: B | REF: 88-91 |
| 10. ANS: A | REF: 88-91 |
| 11. ANS: C | REF: 88-91 |
| 12. ANS: C | REF: 88-91 |
| 13. ANS: A | REF: 88-91 |
| 14. ANS: C | REF: 88-91 |
| 15. ANS: B | REF: 88-91 |
| 16. ANS: C | REF: 88-91 |
| 17. ANS: C | REF: 88-91 |

*Match the correct disease or condition with the descriptions of radiographic appearance.
(Use each choice only once.)*

- a. Tuberculosis
 - b. Emphysema
 - c. Pneumothorax
 - d. Hemoptysis
 - e. COPD (chronic obstructive pulmonary disease)
 - f. Pneumonia
 - g. Atelectasis
 - h. Pleurisy
 - i. Malignant lung cancer
 - j. Pulmonary edema
- 18. Lung displaced from chest wall and no lung markings visible on radiograph
 - 19. Patchy infiltrate with increased radiodensity
 - 20. Increased lung dimensions (barrel-chested)
 - 21. Increased diffuse radiodensity in hilar regions and air-fluid levels
 - 22. Severe cases appear as emphysema
 - 23. Slight shadows in early stages, larger radiopaque masses in advanced stages
 - 24. Collapse of all or part of lung
 - 25. Inflammation of pleura (possible air/fluid levels)
 - 26. A contagious disease caused by airborne bacteria
 - 27. Coughing up blood

- | | |
|------------|---------|
| 18. ANS: C | REF: 89 |
| 19. ANS: F | REF: 89 |
| 20. ANS: B | REF: 89 |
| 21. ANS: J | REF: 89 |
| 22. ANS: E | REF: 89 |
| 23. ANS: I | REF: 89 |
| 24. ANS: G | REF: 89 |
| 25. ANS: H | REF: 89 |
| 26. ANS: A | REF: 89 |
| 27. ANS: D | REF: 89 |

TRUE/FALSE

1. The xiphoid process is a reliable positioning landmark for determining the lower margin of the lungs for chest positioning.

ANS: F REF: 72

2. Geriatric patients generally require higher central ray (CR) centering than younger patients for chest radiography.

ANS: T REF: 82

3. Top of image receptor placed approximately 3 inches (7.6 cm) above the shoulders is a recommended centering technique for adult chest radiography.

ANS: F REF: 86

4. Collimation guidelines indicate the upper border of the collimation field should be approximately 3 inches (7.6 cm) above the vertebra prominens.

ANS: F REF: 86

5. An electrocardiography and echocardiography are the same procedure.

ANS: F REF: 88

6. Scoliosis and kyphosis may produce asymmetry of the sternoclavicular joints and rib cage as demonstrated on a PA chest radiograph.

ANS: T REF: 92

7. For anterior oblique radiographs of the chest, the elongated (widened) aspect of the thorax is generally furthest from the image receptor.

ANS: T REF: 99

8. Contrary to common belief, the vertical dimension of an average PA chest is greater than the horizontal dimension.

ANS: F REF: 80-81

9. A small pneumothorax may be detected by performing inspiration and expiration PA projections.

ANS: T REF: 82

10. The CR is centered to midsternum for the AP apical lordotic projection with a 14- × 17-inch (35- × 43-cm) image receptor (IR).

ANS: T REF: 98

11. When performing the lateral projection of the upper airway, exposure should be made during a slow, deep inspiration rather than at the end of the inspiration.

ANS: T REF: 94-95

12. As a general rule, the use of high kV (110 to 120 kV) requires the use of a grid during chest radiography.

ANS: T REF: 81

13. Epiglottitis is a condition that is primarily seen with geriatric patients.

ANS: F REF: 89