


# Frame Modifications - Forefoot

Information Provided By Kevin Orthopedic Institute



## 1<sup>st</sup> Ray Cut Out

1<sup>st</sup> Ray Cut Out Full  65°  45°  

Frame resection proximal to 1<sup>st</sup> metatarsal head

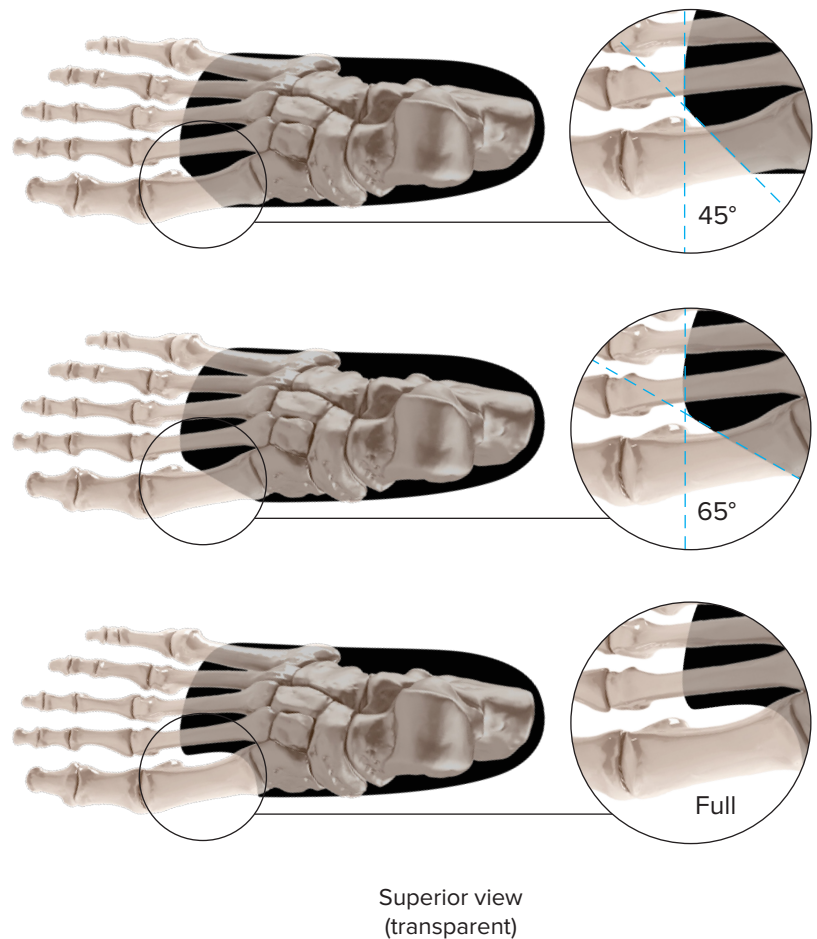

### FUNCTIONS:

- Offloads 1<sup>st</sup> metatarsal head
- Increases 1<sup>st</sup> ray joint excursions

### CLINICAL INDICATIONS:

- Hallux valgus
- Hallux limitus
- Plantarflexed 1<sup>st</sup> rays
- Bunion deformities
- Sesamoiditis

A 1<sup>st</sup> ray cut out is a 45°, 65° or full clipping of the distal medial portion of the orthotic frame. The cut's angulation begins at the 1<sup>st</sup> innerspace of the distal frame and terminates at the medial edge of the frame. A full 1<sup>st</sup> ray cut out is a perpendicular cut at the 1<sup>st</sup> innerspace, runs parallel along the medial 1<sup>st</sup> metatarsal and curves 90° outwards at the 1<sup>st</sup> metatarsal base and terminates at the medial edge of the frame.



**Notes:** All illustrations and diagrams are of right foot  
Colors on illustrations are for visual purposes and will vary on final product