

# Evaluation of a New Wound Closure Device for Linear Surgical Incisions: 3M Steri-Strip S Surgical Skin Closure versus Subcuticular Closure

Carolyn L. Kerrigan, M.D.  
Karen Homa, Ph.D.

Lebanon, N.H.



**Background:** Technological innovations are often adopted before scientific comparison to an accepted standard. The authors' study compared suture with a new coaptive film device, 3M Steri-Strip S Surgical Skin Closure, on linear incisions.

**Methods:** Patients undergoing Wise-pattern breast reduction or abdominal procedures had paired incisions randomly assigned to Steri-Strip S or suture closure. Key outcome measures were closure time, patient comfort, and scar quality at 6 months by patients and surgeons using a new scar evaluation tool, visual assessment of linear scars. Statistical differences between the two closure techniques were assessed by Wilcoxon signed rank test.

**Results:** Of 59 patients, eight were excluded from randomization (a surgeon judged Steri-Strip S to be a nonviable closure technique for mismatched wound edges). Fifty-one patients (breast,  $n = 24$ ; abdomen,  $n = 27$ ) were randomized. Operative time with Steri-Strip S for breast was 2.0 minutes (SD = 1.1) versus suture closure at 4.6 minutes (SD = 1.5;  $p < 0.001$ ). Similarly, Steri-Strip S versus suture for the abdomen was faster ( $p < 0.001$ ; 4.9 minutes, SD = 2.3 versus 10.1 minutes, SD = 3.4). Comfort scores did not differ between closures [5.8 (SD = 2.7) versus 6.9 (SD = 2.0), respectively, on breast ( $p = 0.142$ ) and 7.7 (SD = 1.8) versus 7.7 (SD = 2.3) on abdomen ( $p = 0.903$ )]. Complication rates did not differ between closure types. Patients' visual assessment of linear scars rating of breasts was 3.8 (SD = 2.9) for Steri-Strip S and better at 2.6 (SD = 2.9) for suture ( $p = 0.008$ ). One surgeon rated breast Steri-Strip S scars worse than suture scars (4.3 versus 3.7;  $p = 0.014$ ). For abdominal scars, there was no difference in the patient or surgeon ratings.

**Conclusions:** Steri-Strip S permits faster wound closure than suture. On the basis of patient reports of comfort and scar quality, surgeons increase efficiency and maintain quality with the use of Steri-Strip S on abdominal wounds but not on breast wounds. (*Plast. Reconstr. Surg.* 125: 186, 2010.)

In an effort to increase efficiency in the operating room without sacrificing quality, we undertook a study to evaluate a new wound closure device. New devices and technologies are constantly emerging on the market, and they are often widely adopted before scientific comparison

*From the Section of Plastic Surgery and the Dartmouth-Hitchcock Leadership Preventive Medicine Residency Program, Dartmouth Hitchcock Medical Center.*

*Received for publication December 8, 2008; accepted June 29, 2009.*

*Presented in part at the Annual Meeting of the Canadian Society of Plastic Surgeons, in Banff, Alberta, June of 2007, and at the Annual Meeting of the American Society of Plastic Surgeons, in Baltimore, Maryland, October of 2007.*

*This trial is registered at ClinicalTrials.gov, identifier NCT00727025.*

*Copyright ©2009 by the American Society of Plastic Surgeons*

DOI: 10.1097/PRS.0b013e3181c2a492

to the preexisting accepted standard.<sup>1</sup> For many of the operations performed by plastic surgeons, the lengthy closure time of the procedure adds significantly to the costs, increases anesthetic time, and potentially increases patient risk. New approaches to wound closure<sup>2-4</sup> that result in shortened operative time, while improving or at least not compromising quality, may be justified despite the apparent increase in device cost compared with standard suturing techniques.

The specific goal of this study was to evaluate a new wound closure device, 3M Steri-Strip S Surgical

**Disclosure:** *This study was funded by an unrestricted research grant to the Hitchcock Foundation from 3M Corporation. Dr. Kerrigan is the principal investigator on this grant.*

Skin Closure (Fig. 1) (see **Video, Supplemental Digital Content 1**, demonstrating that the configuration and application of 3M Steri-Strip S Surgical Skin Closure are significantly different from those of standard Steri-Strip, as shown in the stepwise application of Steri-Strip S Surgical Skin Closure on breast incisions, <http://links.lww.com/PRS/A122>), as applied to linear incisions. This device was originally marketed as ClozeX by an independent innovator; when the company was bought out by 3M, the name of the device was changed to Steri-Strip S Surgical Skin Closure and it is currently available on the U.S. market. In a randomized study design, this new device was compared with standard subcuticular suture closure. The three outcome measures were speed of closure, patient 10-day postoperative comfort, and rating the quality of the scar 6 months postoperatively by both the patient and two surgeons. Four hypotheses were tested: (1) surgical time savings can be achieved with Steri-Strip S compared with the suture technique; (2) patient-reported incision comfort in the early postoperative period is not different between Steri-Strip S closure and suture closure; (3) patient ratings of 6-month postoperative scar quality is the same for the Steri-Strip S and the suture technique; and similarly, (4) the two surgeons' ratings of 6-month postoperative scar quality is the same for the Steri-Strip S and the suture technique.

## METHODS

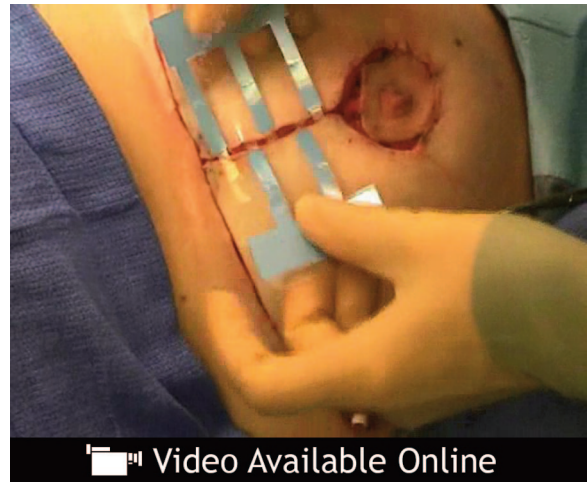### Institutional Review Board

The study was reviewed and approved by the Committee for Protection of Human Subjects at Dartmouth Medical School.

### Patient Enrollment

Patients electing to undergo bilateral breast reduction, abdominoplasty, or transverse rectus abdominis myocutaneous flap were invited to participate in this study between February of 2006 and September of 2007. Patients were eligible for enrollment if they agreed to provide informed consent and were at least 18 years of age.

Supplemental digital content is available for this article. A direct URL citation appears in the printed text; simply type the URL address into any Web browser to access this content. A clickable link to the material is provided in the HTML text of this article on the *Journal's* Web site ([www.PRSJournal.com](http://www.PRSJournal.com)).



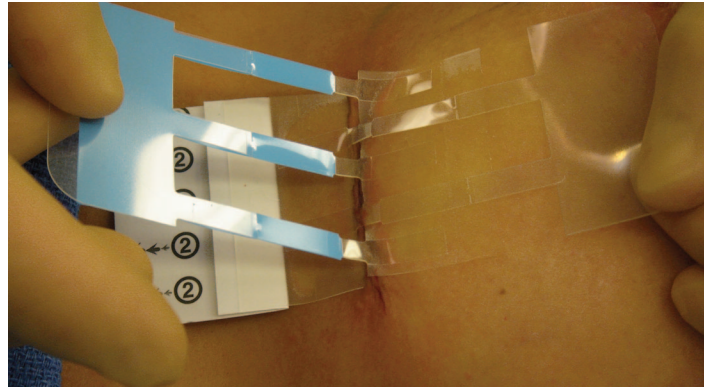
**Video.** Supplemental Digital Content 1 demonstrates that the configuration and application of 3M Steri-Strip S Surgical Skin Closure are significantly different from those of standard Steri-Strip, as shown in the stepwise application of Steri-Strip S Surgical Skin Closure on breast incisions, <http://links.lww.com/PRS/A122>.

### Randomization

The random assignment of closure technique occurred intraoperatively. After resection, hemostasis, and deep dermal closure with Ethicon 4-0 polydioxanone, the randomization envelope was opened. For the breasts, each breast incision was considered to be composed of three segments: vertical, medial, and lateral. The corresponding right and left breast segments were assigned to different closure approaches (Fig. 2). On the abdomen, the right and left sides of the incision were assigned to different closure approaches. Given the external visibility of the closure devices, patients could not be blinded to the randomization and were thus aware of which incisions had been closed with sutures and which with Steri-Strip S.

### Closure Time

By using a handheld stopwatch, the time needed for incision closure was measured in minutes and seconds. The start time was initiated when the surgeon was handed the suture (Ethicon 4-0 polydioxanone) or Steri-Strip S and the stop time when the surgeon called out "finished" following the superficial closure. Dry gauze dressings were applied to all incisions and supported by a surgical bra. Average closure time for each patient and each closure technique was calculated from the three incisions on the breasts. Overall mean closure time for the breast for each closure procedure was then calculated. The overall mean closure time for the abdominal incisions was the av-



**Fig. 1.** 3M Steri-Strip S Surgical Skin Closure device in the process of being applied.

erage of the closure times for each closure technique.

**Comfort Score**

At the 10-day postoperative visit, subjects were asked to assign two ratings of their incisional comfort using a 10-cm visual analogue scale on which “0” was described as very uncomfortable and “10” was described as very comfortable. One rating was for incisions closed with Steri-Strip S and the other for incisions closed by suture.

**Complications**

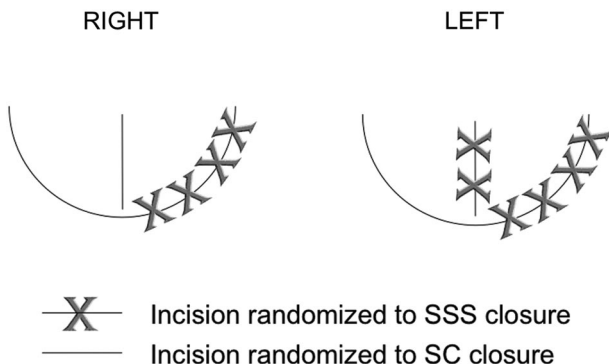
Wound healing complications of infection and dehiscence were recorded.

**Scar Assessment**

Patients rated their own scars 6 months postoperatively, and photographs were taken of the scars so that the surgeons could later rate them. Photographs were taken with a Nikon Coolpix 8400 camera on a macro setting without flash,

using auto-focus and auto-exposure. For better camera focus, a line was drawn on the patient’s skin adjacent to the scar with a surgical pen. Images were uploaded to a computer, cropped, and the size adjusted without color adjustments. These images were printed on white mailing labels (3 1/3” × 4”), which were then applied to standard playing cards and assembled into decks of approximately 50 cards each. The cards had no patient identifiers or closure technique information.

As previously reported, a visual assessment of linear scars tool<sup>5</sup> was developed to rate the quality of a scar. The first step was to sort four “anchor” scar photographs that represent a broad range of scar quality. The patient was asked to sort the four photos from excellent to poor. Then the patient was asked to rate his or her scar relative to the four anchor scars. For example, if the patient thought her scar was better than the best anchor scar, then a “1” was recorded for the scar rating. The research assistant recorded the patients’ scar ratings from 1 to 9 on a data collection form (Fig. 3). The two surgeons were asked to rate the photographs of the scars using the visual assessment of linear scars tool. The surgeons rated approximately 50 cards at a time. Average scar rating for each patient and each closure technique was calculated from the three incisions on the breasts.



**Fig. 2.** Sample breast incision randomization scheme. SSS, Steri-Strip S; SC, sutures.

**Analysis**

The closure time, comfort scores, and scar ratings were slightly skewed, so a Wilcoxon signed rank test was used to determine whether there were significant differences between closure techniques. A *p* value of 0.05 or less was considered statistically significant and data were analyzed using Stata/SE 8.0 (College Station, Texas).

**6-Month Follow Up Survey**  
Steri-Strip S Study

Patient Name: \_\_\_\_\_ Study Number: \_\_\_\_\_  
Date: \_\_\_\_\_ Physician: \_\_\_\_\_

**Step One: Arrange the four (4) scar photos from Best to Worst**  
BEST..... →      →      →      →      WORST

**Step Two: Rating each incision segment**

	1	2	3	4	5	6	7	8	9
Scar 1/A:	<input type="checkbox"/>	<input type="checkbox"/>	<input type="checkbox"/>	<input type="checkbox"/>	<input type="checkbox"/>	<input type="checkbox"/>	<input type="checkbox"/>	<input type="checkbox"/>	<input type="checkbox"/>
Scar 2/B:	<input type="checkbox"/>	<input type="checkbox"/>	<input type="checkbox"/>	<input type="checkbox"/>	<input type="checkbox"/>	<input type="checkbox"/>	<input type="checkbox"/>	<input type="checkbox"/>	<input type="checkbox"/>
Scar 3:	<input type="checkbox"/>	<input type="checkbox"/>	<input type="checkbox"/>	<input type="checkbox"/>	<input type="checkbox"/>	<input type="checkbox"/>	<input type="checkbox"/>	<input type="checkbox"/>	<input type="checkbox"/>
Scar 4:	<input type="checkbox"/>	<input type="checkbox"/>	<input type="checkbox"/>	<input type="checkbox"/>	<input type="checkbox"/>	<input type="checkbox"/>	<input type="checkbox"/>	<input type="checkbox"/>	<input type="checkbox"/>
Scar 5:	<input type="checkbox"/>	<input type="checkbox"/>	<input type="checkbox"/>	<input type="checkbox"/>	<input type="checkbox"/>	<input type="checkbox"/>	<input type="checkbox"/>	<input type="checkbox"/>	<input type="checkbox"/>
Scar 6:	<input type="checkbox"/>	<input type="checkbox"/>	<input type="checkbox"/>	<input type="checkbox"/>	<input type="checkbox"/>	<input type="checkbox"/>	<input type="checkbox"/>	<input type="checkbox"/>	<input type="checkbox"/>

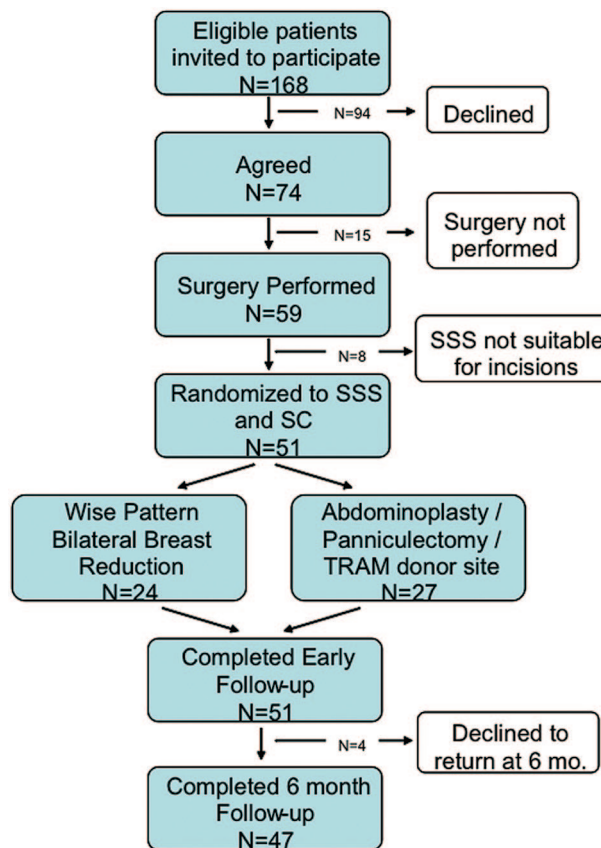
**Fig. 3.** Data collection sheet for patients' scar ratings at 6 months.

### RESULTS

Of the 168 eligible patients, 74 agreed to participate (Fig. 4). Fifty-nine patients underwent surgery; however, eight were excluded due to the Steri-Strip S not being a viable closure technique as judged by the surgeon. This occurred when there was significant discrepancy in the opposing wound edges, and of these eight cases, six were patients with abdominal wounds and two with breast wounds. Thus, 51 patients were randomized. Twenty-four patients underwent bilateral breast reductions (all female), and 27 underwent abdominal procedures (24 female and three male).

#### Time

There were a total of 198 scar segments ( $27 * 2 = 54$  for abdomen and  $24 * 6 = 144$  for the breasts) for closure time evaluation. The mean time for closure of breast incision segments with Steri-Strip S was 2.0 minutes (SD = 1.1; 95 percent CI = 1.6 to 2.5) and for closure with suture was 4.6 (SD = 1.6; 95 percent CI = 3.9 to 5.2). The mean difference of 2.5 minutes between closure techniques was significantly different ( $p < 0.001$ ). Thus, the mean time to perform the six-incision procedure on the breasts using Steri-Strip S would be 12.4 minutes and 27.7 minutes with suture. This represents a potential savings of 15.2 minutes of operative time by choosing to use Steri-Strip S for closure over suture (Fig. 5).



**Fig. 4.** Patient enrollment.

The mean time for closure of abdominal incision segments with Steri-Strip S was 4.9 minutes (SD = 2.3; 95 percent CI = 4.0 to 5.8) and with suture was 10.1 minutes (SD = 3.4; 95 percent CI = 8.7 to 11.5). The mean difference of 5.2 minutes between closure techniques was significantly different ( $p < 0.001$ ). The mean time for closure of the full abdominal incision would thus be 9.9 minutes using Steri-Strip S and 19.6 minutes using suture. This would thus save 9.7 minutes of operative time by choosing to use Steri-Strip S for closure over suture.

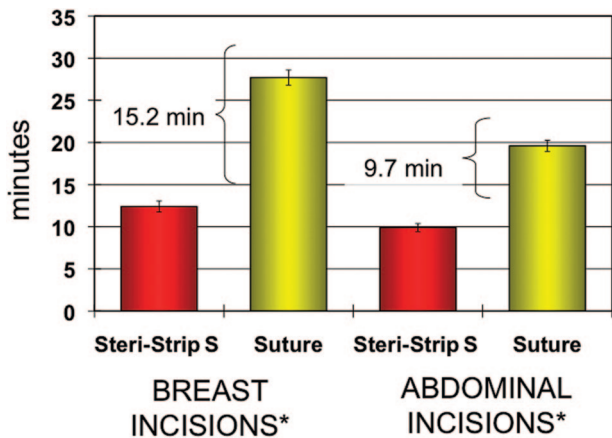
**Comfort**

Twenty-five of the 27 patients with abdominal procedures and 23 of the 24 patients with breast

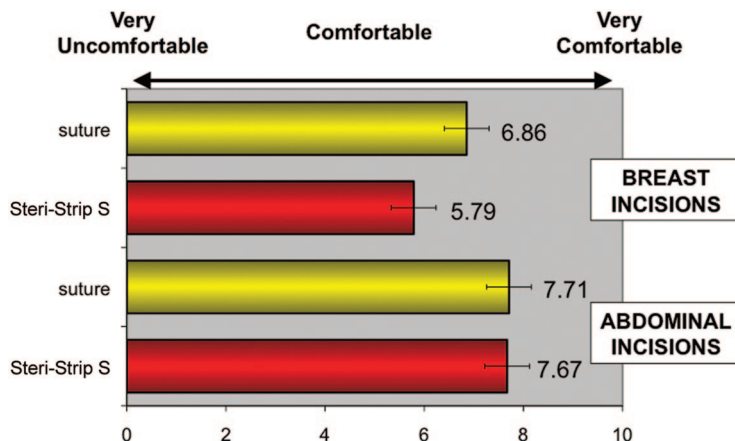
procedures were available to collect comfort score data. The mean comfort visual analogue scale rating scores (higher scores are better) for breast incisions closed with Steri-Strip S was 5.8 (SD = 2.7; 95 percent CI = 4.6 to 7.0) and with sutures was 6.9 (SD = 2.0; 95 percent CI = 6.0 to 7.7). The mean difference of 1.1 scale between closure techniques was not significantly different ( $p = 0.142$ ). For abdominal incisions, the mean comfort scores for Steri-Strip S were 7.7 (SD = 1.8; 95 percent CI = 6.9 to 8.4) and with sutures was 7.7 (SD = 2.3; 95 percent CI = 6.8 to 8.7). There was no statistical difference between the closure techniques for the abdomen ( $p = 0.903$ ) (Fig. 6).

**Complications**

Of the 27 patients with abdominal surgery, two patients had reported wound healing complications. One with cellulitis at the drain site and incision segment closed with sutures. The other with cellulitis in the suprapubic region at the juncture of sutures and Steri-Strip S closed wounds. Both responded to oral antibiotics. Of the 24 patients with breast reduction surgery, there was one patient with wound healing complications. On one side, there was a minor wound dehiscence in the vertical scar segment that had been closed by suture, and on the other side, there was a <1 cm dehiscence at the T-juncture where the vertical and lateral inframammary wounds closed with suture met with the medial inframammary wound closed with Steri-Strip S. This wound healed secondarily with local wound care.



**Fig. 5.** Time for closure (with SE bars) of the superficial skin layer using Steri-Strip S compared with suture for both breast reduction and abdominal incisions. \*Closure technique was significantly different;  $p < 0.001$ .



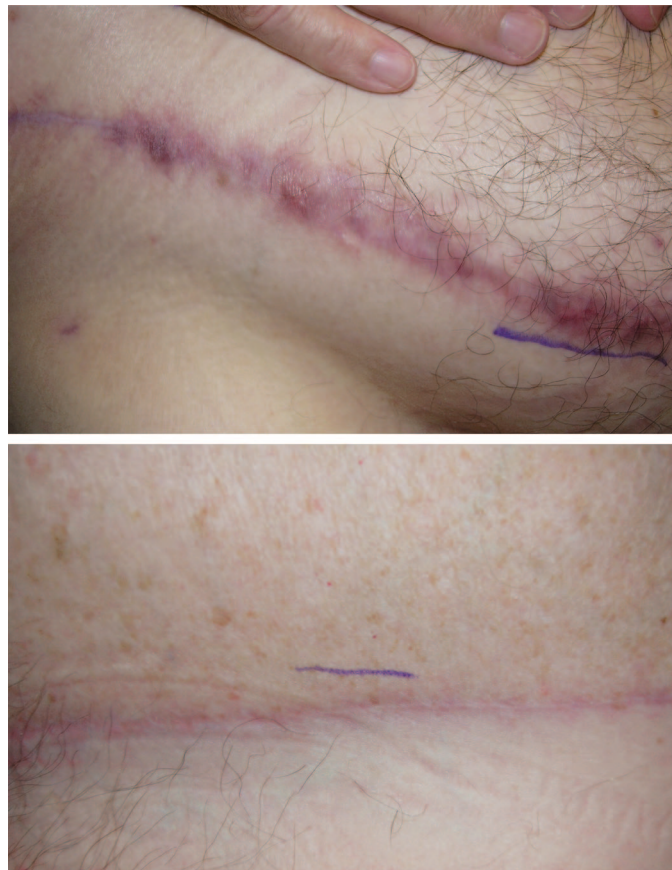**Fig. 6.** Patient ratings: average visual analogue scale comfort scores (with standard error bars) at the 10-day postoperative visit for the abdomen ( $n = 25$  each group; paired  $t$  test,  $p = 0.936$ ) and breast ( $n = 23$  each group; paired  $t$  test,  $p = 0.067$ ).

### Six-Month Postoperative Scar Quality

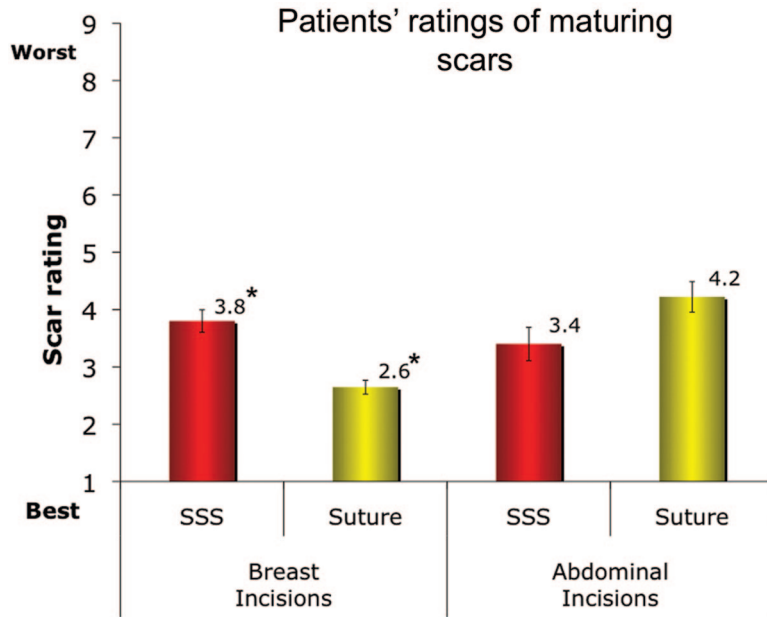
Scars were evaluated on average at 6.4 months postoperatively (median, 6.3 months; range, 2.7 to 12.2 months). Four patients did not return for their 6-month postoperative visit. Forty-seven patients completed the 6-month scar evaluation (92 percent follow-up rate; 22 patients with breast reduction and 25 patients with abdominal procedures). Representative patient scars are shown in Figure 7. The patient ratings of their scars were significantly different between closure technique ( $p = 0.008$ ) for the breast. The average visual assessment of linear scars score (lower score is better) for Steri-Strip S was 3.8 (SD = 2.9) and for suture was 2.6 (SD = 2.1). For the abdominal scars, the patient ratings between Steri-Strip S and suture were not different ( $p = 0.595$ ). The Steri-Strip S closure average was 3.4 (SD = 2.6) compared with suture with an average rating of 4.2 (SD = 2.9) (Fig. 8).

Two surgeons rated photographs of the patients' scars. Some patients' photographs were judged of insufficient quality for rating; therefore, surgeons 1 and 2 rated 20 breast reduction patients' scars. Surgeon 1's scar ratings were statistically significantly different between closure technique ( $p = 0.014$ ) for the breast (Fig. 9). The average visual assessment of linear scars score (lower is better) for the Steri-Strip S was 4.3 (SD = 1.4) and for suture was 3.7 (SD = 1.5). For surgeon 2, the breast ratings between Steri-Strip S and suture were not significantly different ( $p = 0.112$ ). For surgeon 2, the average visual assessment of linear scars score for the Steri-Strip S was 4.7 (SD = 1.9) and for suture was 4.2 (SD = 2.4).

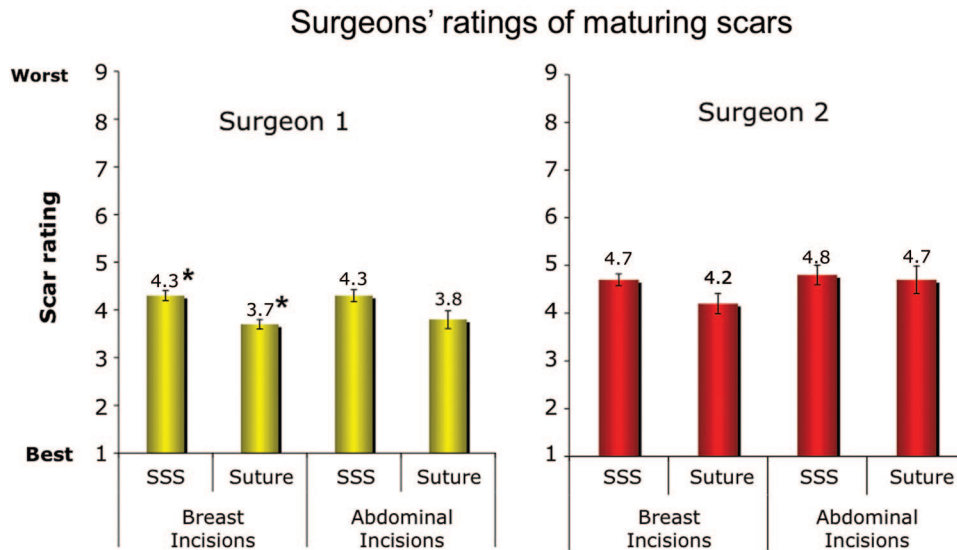
Surgeon 1 rated 23 abdomen procedure patients' scars, whereas surgeon 2 rated 22 of the patients' scars. Surgeon 1's scar ratings showed that closure technique was not significantly different ( $p = 0.087$ ). The average visual assessment



**Fig. 7.** Sample images of poor scars and excellent scars, both closed with Steri-Strip S. Using visual assessment of linear scars, the poor scar (*above*) was rated 9, 7, and 9 by the patient, surgeon 1, and surgeon 2, respectively. The excellent scar (*below*) was rated 1, 2, and 2, by the patient, surgeon 1, and surgeon 2, respectively.



**Fig. 8.** Patient ratings: means for 6-month scar ratings (with *standard error bars*) for both location and closure. \*Closure technique resulted in significantly different breast scar ratings;  $p = 0.008$ .



**Fig. 9.** Surgeon ratings: 6-month average scar ratings (with SE bars) for location and closure type. \*Surgeon 1: closure technique resulted in significantly different breast scar ratings;  $p = 0.013$ .

of linear scars score for the Steri-Strip S was 4.3 (SD = 1.2) and for suture was 3.8 (SD = 1.7). For surgeon 2, ratings between Steri-Strip S and suture were also not different ( $p = 0.598$ ). For surgeon 2, the average visual assessment of linear scars score for the Steri-Strip S was 4.8 (SD = 1.9) and for suture was 4.7 (SD = 2.6).

### DISCUSSION

There are four key primary findings of this study. First, surgical time efficiency was increased with use of Steri-Strip S closure of both breast and abdominal incisions as compared with standard suture closure. Second, patients report a modest decrease in comfort from Steri-Strip S closure

compared with suture closure on breast wounds, which approaches statistical significance, but no difference in comfort for abdominal wounds. Third, patients rating their own scars judged the breast scars to be better when closed with sutures than with Steri-Strip S, by 1.2 scale units, and the abdominal scars to be of equal quality. Fourth, surgeons rating photographs of the maturing scars found no differences in quality with closure method in the abdomen, but one surgeon did find better scar quality in the breast with suture compared with Steri-Strip S, by 0.6 scale units.

When interpreting the clinical application of these four key findings, it becomes a challenge to determine whether statistical significance is a reasonable proxy for the minimal clinically important difference. It can certainly be argued that a scale difference of 0.6 units on the visual assessment of linear scars is not a clinically meaningful difference. Quinn and Wells<sup>6</sup> suggest that on a 100-mm visual analogue scale used for scar assessment, the minimal clinically important difference is 13 to 15 mm. Thus, despite statistical significance in our study, one could conclude that neither surgeon found a clinically meaningful difference in the scar quality. Further study of visual assessment of linear scars as a measurement tool could include computation of its minimal clinically important difference.

From the combined study results for closure of abdominal incisions, the use of Steri-Strip S can be supported over suture closure because of the increase in efficiency without compromise of quality as judged by patient comfort and 6-month post-operative scar quality. In the case of breast incision closure, it becomes an interesting challenge to balance the findings of increased surgical efficiency of a significant nature to a slight increase discomfort experienced by the patients and a slight worsening of the scar as evaluated by patients and one of the surgeons. Does efficiency or comfort and scar quality trump the other? Seen from one surgeon's perspective, the improved surgical efficiency was important as the surgeon did not report any difference in scar quality. From the patients' perspective, however, the modest increase in discomfort and the modest poorer quality scar for the breast should likely trump the increased efficiency. In the case of abdominal closure, patients and surgeons were in agreement that there is no difference in scar quality, patients experience equivalent comfort from the two closure techniques, and thus there is no reason not to benefit from the potential increased efficiency. Our findings would thus support the use

of Steri-Strip S for the closure of abdominal wounds and would question its benefit in the closure of breast reduction wounds. Of note, the Steri-Strip S design used in this study had squared corners. Based on feedback from early data in this study, the manufacturers have redesigned the product to have rounded corners that may well improve comfort for patients. In another article, we will report on an economic analysis to further explore the opportunity costs of increased efficiency.

A potential study bias was that the patients were not blinded to their closure technique. If they experienced greater discomfort with the Steri-Strip S and if they recalled the specific breast incision segment thus closed, they might bias their scar ratings in favor of suture closure. Another potential source of bias was that surgeons were rating photographs of scars, while the patients were rating their actual scars. Although both were rating the scar in comparison to four anchor photographs, there may be some error due photographic quality. The patients were Caucasian, and therefore these results on comfort and scar quality may not be generalizable to all ethnic groups. In addition, only two surgeons rated the scars. Time efficiency may vary due to surgeon experience and evaluation of maturing scar quality may be surgeon dependent.

Further research, possibly a focus group with patients, would further our understanding of patient expectations of postsurgical outcomes relative to scar appearance and might elucidate further understanding of whether a one scale difference on the visual assessment of linear scars tool is an important difference.

We conclude that use of Steri-Strip S for transverse abdominal wound closure can be justified on a time efficiency basis without compromise in quality as judged by both surgeons and patients. Use of the original design of Steri-Strip S for closure of a Wise-pattern breast reduction, however, cannot be justified when considering patients' perspectives, despite the potential increased time efficiency. It is possible that the newer design of the Steri-Strip S with rounded corners may increase patient comfort in areas of skin folds and be more acceptable to patients.

*Carolyn L. Kerrigan, M.D.*  
Dartmouth Hitchcock Medical Center  
One Medical Center Drive  
Lebanon, N.H. 03756  
Carolyn.L.Kerrigan@hitchcock.org



**ACKNOWLEDGMENTS**

The authors thank Thom Walsh, M.S., for his participation in the initial design and start-up of the study, Margaret Meyer, N.P., for her study coordination skills, Renee Comizio, M.D., for rating scars, and Todd Burdette, M.D., for manuscript review and assistance with image preparation.

**REFERENCES**

1. Leff B, Finucane TE. Gizmo idolatry (commentary). *JAMA*. 2008;299:1830–1832.
2. Ruff GL. Technique and uses for absorbable barbed sutures. *Aesthet Surg J*. 2006;26:620.
3. Vogt PA. Evaluation of a novel absorbable subcuticular skin stapler in plastic surgery. 2007. Available at: <http://www.insorb.com/pdfs/VogtPlasticSurgeryWhitePaper.pdf>. Accessed July 20, 2008.
4. Nipshagen MD, Hage JJ, Beekman WH. Use of 2-octyl-cyanoacrylate skin adhesive (Dermabond) for wound closure following reduction mammoplasty: A prospective, randomized intervention study. *Plast Reconstr Surg*. 2008;122:10–18.
5. Kerrigan CL, Homa KA. Visual Assessment of Linear Scars (VALS): A new tool. *Plast Reconstr Surg*. 2009;124:1513–1519.
6. Quinn JV, Wells GA. An assessment of clinical wound evaluation scales [see comment]. *Acad Emerg Med*. 1998;5:583–586.

**Online CME Collections**

This partial list of titles in the developing archive of CME article collections is available online at [www.PRSJournal.com](http://www.PRSJournal.com). These articles are suitable to use as study guides for board certification, to help readers refamiliarize themselves on a particular topic, or to serve as useful reference articles. Articles less than 3 years old can be taken for CME credit.

**Reconstructive****Trunk**

**Donor-Site Morbidity Comparison between Endoscopically Assisted and Traditional Harvest of Free Latissimus Dorsi Muscle Flap**—Chih-Hung Lin et al.

**Reconstruction of a Severe Chest and Abdominal Wall Electrical Burn Injury in a Pediatric Patient**—Craig MacKinnon et al.

**The Separation of Anatomic Components Technique for the Reconstruction of Massive Midline Abdominal Wall Defects: Anatomy, Surgical Technique, Applications, and Limitations Revisited**—Kenneth C. Shestak et al.

**Endoscopically Assisted “Components Separation” for Closure of Abdominal Wall Defects**—James B. Lowe et al.

**An Algorithm for Abdominal Wall Reconstruction**—Rod J. Rohrich et al.

**The Surgical Treatment of Brachial Plexus Injuries in Adults**—Julia K. Terzis and Vasileios K. Kostopoulos  
**Pharmacologic Optimization of Microsurgery in the New Millennium**—Matthew H. Conrad and William P. Adams, Jr.

**Risks Associated with “Components Separation” for Closure of Complex Abdominal Wall Defects**—James B. Lowe, III, et al.

**The Surgical Treatment of Obstetric Brachial Plexus Palsy**—Saleh M. Shenaq et al.

**Tissue Engineering: Progress and Challenges**—Mark A. F. Knight and Gregory R. D. Evans

**Fire in the Operating Room: Principles and Prevention**—Stephen P. Daane and Bryant A. Toth

**Gender Identity Disorder: General Overview and Surgical Treatment for Vaginoplasty in Male-to-Female Transsexuals**—Gennaro Selvaggi et al.

**Further Clarification of the Nomenclature for Compound Flaps**—Geoffrey G. Hallock

**Burn Injuries Inflicted on Children or the Elderly: A Framework for Clinical and Forensic Assessment**—Adam R. Greenbaum et al.

**Management of Posterior Trunk Defects**—David Mathes et al.

**Platelet-Rich Plasma: A Review of Biology and Applications in Plastic Surgery**—Barry L. Eppley et al.

**Microvascular Surgery**—Brandon C. D. Evans and Gregory R. D. Evans

**Basics of Immune Responses in Transplantation in Preparation for Application of Composite Tissue Allografts in Plastic and Reconstructive Surgery: Part I**—Maria Siemionow and Aleksandra Klimczak

**Acute Burns**—Chia Chi Kao and Warren L. Garner