

## Coaptive Film *Versus* Subcuticular Suture

### Comparing Skin Closure Time After Posterior Spinal Instrumented Fusion in Pediatric Patients With Spinal Deformity

Brian E. Grottkau, MD, Gleeson Rebello, MD, Gabriel Merlin, BA,  
and Jonathan M. Winograd, MD

**Study Design.** A prospective, randomized trial comparing skin closure time between coaptive film and subcuticular Monocryl sutures in children undergoing posterior instrumented spinal fusion.

**Objective.** To prospectively compare skin closure time, complication rate and cosmetic result between coaptive film and subcuticular Monocryl wound closures in pediatric spine surgery.

**Summary of Background Data.** Posterior instrumented spinal fusions for spinal deformity in children are time-consuming ventures that are demanding on both the patient and physician. Minimizing the time for skin closure at the end of prolonged surgery diminishes the physical burden on the surgeon, the operating room personnel, and reduces operating room costs.

**Methods.** Twenty-five children (mean age, 14.1 year) underwent posterior instrumented spinal fusion. Twenty-five incisions in 25 patients (12 closed with 3-0 subcuticular Monocryl sutures, 13 closed with coaptive film [Steri-Strip S; 3 M company]) were evaluated. The method of skin closure was randomized before beginning the procedure and the surgeon informed just before skin closure. Closure time was recorded. A blinded plastic surgeon using a visual analogue scale assessed the cosmetic results at a minimum 3-month follow-up.

**Results.** Incisions closed with coaptive film required less time to complete than incisions closed with subcuticular suture. The mean time for skin closure using coaptive film was 290.62 seconds compared to the mean time of 674.75 seconds using Monocryl sutures ( $P < 0.000001$ ). The average length of incisions closed with coaptive film was similar to the corresponding incisions that were closed with subcuticular Monocryl sutures (30.8 and 34.0 cm, respectively,  $P = 0.22$ ). There was no significant difference in the cosmetic results or the number of wound complications using either technique.

**Conclusion.** Coaptive film is a time-saving option for skin closure following pediatric spine surgery with comparable cosmetic results and no difference in complication rates.

**Key words:** scoliosis, kyphosis, spinal deformity, skin closure, time for closure. **Spine 2010;35:2027–2029**

Posterior instrumented spinal fusions for scoliosis can be time-consuming ventures. Minimizing the time for skin closure at the end of a prolonged surgery diminishes the physical burden on the patient, surgeons, and operating room personnel and reduces operating room costs. An ideal method of incision closure is reliable, time-efficient, inexpensive, and produces optimal cosmetic outcome.

Wound closure techniques following surgery include synthetic sutures, absorbable sutures, staples, tapes, and adhesive compounds. Absorbable subcuticular sutures are frequently used in the pediatric age group because suture and staple removal can cause anxiety. Recently, coaptive film has been introduced as a primary skin closure technique.<sup>1</sup> After the skin incision heals, the film falls off on its own and does not require formal removal, which makes it an attractive option in children.

Our study is a blinded, randomized, controlled study comparing skin closure time and cosmesis between coaptive film and subcuticular Monocryl sutures in children undergoing surgery for spinal deformity. The coaptive film used in this study is commercially known as Steri-Strip S and was formerly known as ClozeX.

#### Materials and Methods

We studied 25 children under 18 years of age with spinal deformity who underwent posterior instrumented fusion. There were 7 males and 18 females. The mean age of the patients was 14.1 years. Patients with known allergy to surgical tape, morbid obesity with a BMI of  $>35$ , or history of keloid scar formation were excluded from the study.

Skin closure in each patient was randomized to skin closure with either coaptive film or subcuticular sutures. Indications for surgery included idiopathic scoliosis and kyphosis. The average number of levels fused in each group was 11.3. A total of 25 incisions were closed in 25 patients. Twelve incisions were closed with 3-0 subcuticular Monocryl sutures and 13 were closed with coaptive film (Steri-Strip S; 3 M company, 3 M Center St. Paul, MN).

The time taken for skin closure in seconds was recorded. The start time occurred once the surgeon asked for either the coaptive film or the 3-0 Monocryl suture and it was placed in his hand. The end time was recorded once the final coaptive film was deemed to be in place or once the last conventional steri-strip was placed over the incision closed with subcuticular suture. Before skin closure in both groups, the underlying fascia was closed with 1 Vicryl and the subcutaneous tissue was closed with 2-0 undyed Vicryl. Please refer to Figures 1A and 1B for demonstration of technique of application of coaptive film.

From the Department of Pediatric Orthopedics, MassGeneral Hospital for Children, Boston, MA.

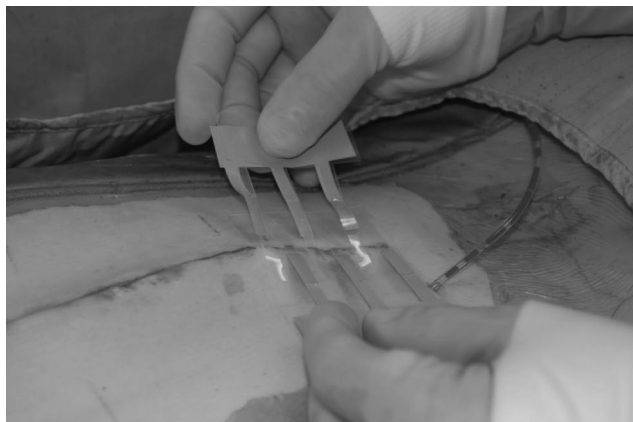
Acknowledgment date: August 22, 2009. First revision date: October 5, 2009. Acceptance date: October 7, 2009.

Supported by 3M Corporation.

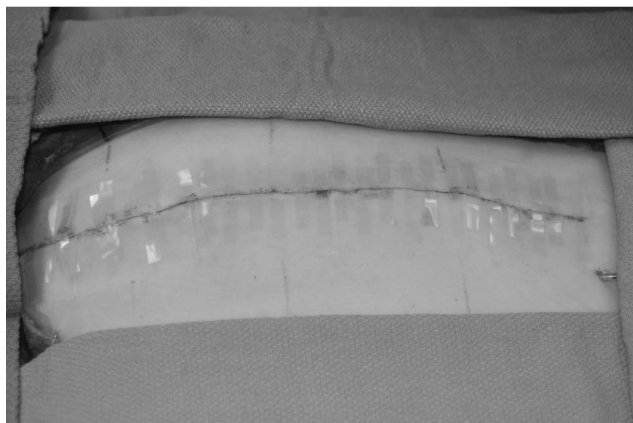
The device(s)/drug(s) is/are FDA-approved or approved by corresponding national agency for this indication.

Corporate/Industry funds were received in support of this work. No benefits in any form have been or will be received from a commercial party related directly or indirectly to the subject of this manuscript.

Address correspondence and reprint requests to Brian E. Grottkau, MD, Department of Pediatric Orthopedics, MassGeneral Hospital for Children, 55 Fruit St, YAW 3400, Boston, MA 02114; E-mail: bgrottkau@partners.org



A



B

Figure 1. **A, B** The technique of application of coaptive film. The skin surface has to be completely dry before application. Strips of film (varying lengths are available) with connecting tabs are applied to skin on either side of incision. Connecting tabs are pulled across to close the incision and stuck down on the film at the desired tension. The excess film is removed.

■ **Results**

The incisions closed with coaptive film required less time for closure when compared to the incisions closed with subcuticular suture. The average time for skin closure using Monocryl sutures was 674.75 seconds compared to the average time of 290.62 seconds using coaptive film ( $P < 0.000001$ ). The average length of skin incision for the total group was 32.25 cm. The average incision lengths closed with Monocryl sutures was 33.95 cm compared to an average of 30.80 cm closed with coaptive film ( $P = 0.22$ ). Please refer to Table 1 for complete results.

Cosmetic differences were assessed by a blinded plastic surgeon using a 0 to 10 visual analogue scale (10 is the highest score). The Monocryl sutures scored 5.17 and the coaptive film scored 5.15. ( $P = 0.99$ ). There were no instances of infection or wound dehiscence using either technique. Figures 2A and 2B depict cosmetic result using coaptive film and subcuticular closure respectively.

■ **Discussion**

Different closure techniques have been compared using controlled studies following surgical procedures varying from arthroplasty to breast surgery.<sup>2-6</sup> Closure techniques studied include tissue adhesives, subcuticular suture, and staples. Tissue adhesives and subcuticular skin closure using Monocryl are attractive options for skin closure following surgery in children as neither subject a child to the trauma of suture or staple removal. Furthermore, tissue adhesives appeal to physicians because they do not pose a needle stick concern.

A study conducted by Ong *et al* in the pediatric age group following herniotomies compared tissue adhesive 2-Octylcyanoacrylate (Dermabond) *versus* subcuticular suture. The study inferred that tissue glue is easy to use with no complications and has equivalent cosmetic results, but is not faster with regards to application time than subcuticular suture.<sup>2</sup> In a prospective, randomized study of children undergoing single-session bilateral lower extremity surgery, Rebello *et al*<sup>7</sup> found coaptive film to be time saving with a similar complication rate and comparable cosmetic results to subcuticular suture closure. Khan *et al* compared the effectiveness of skin closure using Dermabond, sutures, and staples following joint arthroplasty.<sup>3</sup> The study determined that Dermabond should not be used, due to worse cosmesis and a higher wound complication rate, and that staples are better than sutures in regards to time efficiency. However, staple removal can cause discomfort that diminishes its utility in the pediatric age group.

Kuo *et al* compared the effectiveness of coaptive film *versus* simple running suture in patients referred for excision of benign and malignant cutaneous lesions. The mean incision size was 5.7 cm and coaptive film saved an average of 127 seconds in comparison to the simple running suture. From a cosmetic perspective, according to both physicians and patients, coaptive film was superior to sutures in Kuo's study. There was no difference in the incidence of wound dehiscence using either technique.<sup>1</sup>

**Table 1. Contains the Number of Incisions and Compares the Minimum Value, Maximum Value, Mean, Range and Standard Deviation for Length of Closure, Time of Closure, and Score of Closure Between Coaptive Film and Monocryl**

Material	No. Incisions	Minimum Length (cm)	Maximum Length (cm)	Mean Incision Length (cm)	Range Length (cm)	Minimum Time for Closure (s)	Maximum Time for Closure (s)	Mean Time for Closure (Seconds)	Range Time for Closure (s)	Minimum Cosmetic Score (1-10)	Maximum Cosmetic Score (1-10)	Mean Cosmetic Score (1-10)	Range Cosmetic Score (1-10)
Coaptive film	13	17.0	45.5	30.80	28.5 ± 6.44	125	513	290.62	388 ± 98.28	1	9	5.15	8 ± 2.38
3-0 Monocryl	12	28.0	45.0	33.95	17.0 ± 7.25	312	1084	674.75	772 ± 198.67	2	7	5.17	5 ± 1.75
<i>P</i>				0.22				<0.000001				0.99	

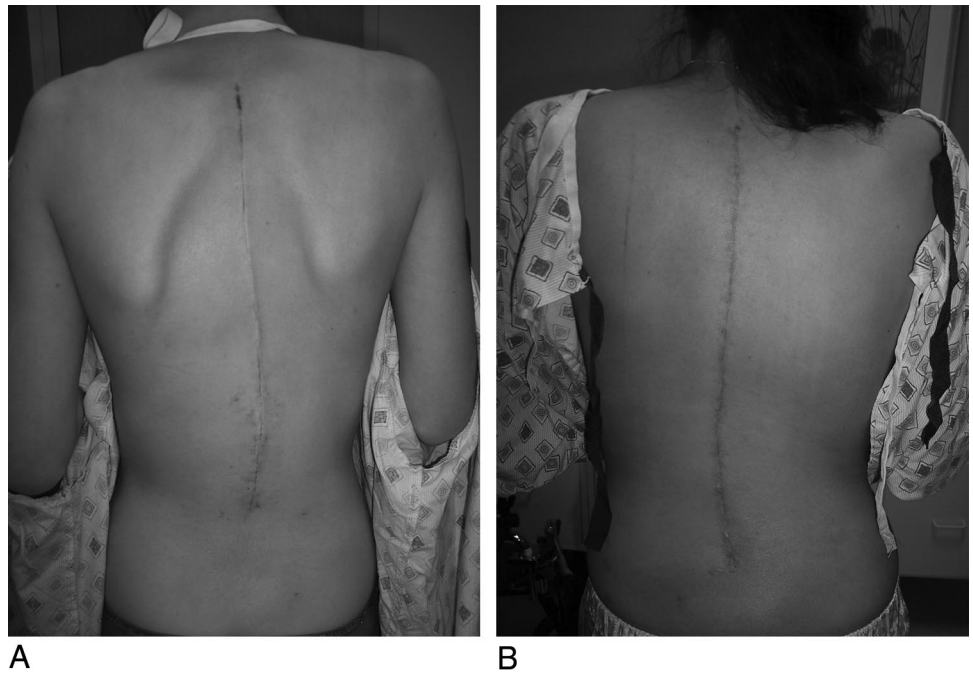


Figure 2. **A** (coaptive film) and **B** (Monocryl) show closure techniques used and 3-month follow-up pictures following spinal fusion.

In this study, we compared time required for closure of skin incisions following posterior instrumented spinal fusions using either coaptive film or subcuticular closure with 3-0 Monocryl. We determined that coaptive film application requires significantly less time than subcuticular closure using Monocryl for wound closure. In the numbers studied, there was no difference in the cosmetic results and no instances of wound dehiscence using either technique.

Use of coaptive film for posterior spinal wound closure in children has the potential to save significant resources because of high operating room costs. When one accounts for the thousands of similar surgeries taking place in hospitals each year, the use of coaptive film has the potential to save a substantial amount of hospital resources nationally, and diminishes the financial burden on the healthcare system. The retail cost of the coaptive film is \$20.00 for a 40 mm length and \$33.00 for an 80 mm length. This is costlier than the \$4.50 for a 3-0 Monocryl suture. This price difference pales, however, when OR costs are considered. The average charge for the main OR time at our institution is \$2259 for every 0 to 30 minute block, which averages \$75.30 per minute. In the Same Day Surgical Unit, the charges are \$1927 for every 0 to 30 minutes, which averages \$64.20 a minute. The cumulative effect of reducing these costs summated over the thousands of surgeries done per year nationwide can reduce the financial burden on individual hospitals and the healthcare system, greatly improving the cost effectiveness of current practice by using coaptive film instead of Monocryl sutures.

The ease and the speed of application coupled with the safety of needle-less skin closure makes coaptive film an attractive option for wound closure. The acceptable

cosmetic result coupled with the ability of the coaptive film to fall off on its own once the incision has healed facilitates its use in children.

#### ■ Key Points

- Use of coaptive film is thought to be a time saving option with similar cosmetic results.
- Time saved diminishes the physical burden on the patient, the surgeons, and the operating room personnel and saves OR resources.
- Coaptive film is technically easy to apply with a minimal learning curve.
- Coaptive film is a cost effective and reliable technique for skin closure.

#### References

1. Kuo F, Lee D, Rogers GS. Prospective, randomized, blinded study of a new wound closure film versus cutaneous suture for surgical wound closure. *Dermatol Surg* 2006;32:676–81.
2. Ong CC, Jacobsen AS, Joseph VT. Comparing wound closure using tissue glue versus subcuticular suture for pediatric surgical incisions: a prospective, randomized trial. *Pediatr Surg Int* 2002;18:553–5.
3. Khan RJ, Fick D, Yao F, et al. A comparison of three methods of wound closure following arthroplasty: a prospective, randomized controlled trial. *J Bone Joint Surg Br* 2006;88:238–42.
4. Switzer EF, Dinsmore RC, North JH Jr. Subcuticular closure versus Dermabond: a prospective randomized trial. *Am Surg* 2003;69:434–6.
5. Zempsky WT, Parotti D, Grem C, et al. Randomized controlled comparison of cosmetic outcomes of simple facial lacerations closed with Steri Strip Skin Closures or Dermabond tissue adhesive. *Pediatr Emerg Care* 2004;20:519–24.
6. Gennari R, Rotmensz N, Ballardini B, et al. A prospective, randomized, controlled clinical trial of tissue adhesive (2-octylcyanoacrylate) versus standard wound closure in breast surgery. *Surgery* 2004;136:593–9.
7. Rebello G, Parikh R, Grottkau B. Coaptive film versus subcuticular suture: comparing skin closure time following identical, single-session, bilateral limb surgery in children. *J Pediatr Orthop*. 2009, 29(6):626–8.