

## General Healthcare Users Training Guide

### The Closure Goal

The objective is to learn how to identify a laceration that is appropriate for Clozex Closures, and also learn how to close a wound in a manner that keeps the patient comfortable, minimizes the risk of infection, and produces minimal scarring.

### Wound Assessment

Evaluation of a patient with a wound/laceration begins with controlling/stopping blood loss and checking for more serious patient problems or injuries. While Clozex Closures are excellent for closing lacerations, there are many conditions that would require more serious medical attention, that are best suited for a hospital.

### The Patient Exam

**The patient should be made comfortable as a first step.** A caring, professional exam should reduce patient stress. Make sure the patient is speaking normally and is not suffering from mental status changes or any extraordinary pain or discomfort. If the wound is clean and the patient has not had a tetanus shot within 10 years, he/she will require one. If the wound is dirty and the patient has not had a tetanus shot within 5 years, he/she will require one. If the laceration is from an animal bite, a rabies history of both patient and animal will have to be undertaken, and the patient may require rabies IG treatment and the vaccination series. Many bites (animal or human) are not closed primarily, depending on the location and size, to minimize chance of infection. A patient with an animal bite is best managed at a hospital or an ED. **If there are any other serious complications discovered or suspected, the patient should be taken to the Emergency Department.**

### The Wound Exam

Check the immediate wound area. The following indications require the patient be taken to the Emergency Department.

- ▶ Severe bleeding that can't be controlled.
- ▶ Deformity or tenderness in the immediate and surrounding area.
- ▶ Excessive amounts of skin oil or moisture where adhesion may be compromised.
- ▶ Skin flaps (large areas of skin that lift and flop open, exposing the underlying tissue).
- ▶ Deep lacerations (more than ½ inch).
- ▶ Significant swelling.
- ▶ Wounds greater than 10 hours old.
- ▶ Human or animal bites.
- ▶ Wounds over major joints, or hard-to-reach places, eyes, nose, ears.
- ▶ Significant contamination with dirt or other foreign bodies
- ▶ Excessive hair that's difficult to shave (scalp, pubic area)
- ▶ Patient's with known severe reactions to adhesive tapes.

## Patient Preparation

**Prior to wound preparation, most patients may be fearful of the need for some form of needle for the closure.** Explain to the patient that the Clozex closure process does not use any needles because the laceration is closed with topically applied tapes. Reviewing these Clozex features will further reduce the patient's anxiety - especially in children.

Ask if the patient or patient advocate has tried to clean or care for their wound. You should ask about any treatments that the patient has tried, and the approximate age of the wound to determine if it can be successfully closed with Clozex.

## Lowering the Risk of Wound Infections

**The source and setting of the injury is important to help identify the presence of wound contaminants and foreign bodies, which can result in infection and/or delayed healing.** The risk of infection is much higher if wound contamination is visible. In such cases the wound will require more extensive cleansing.

The forces causing the injury can also help predict the likelihood of infection. The most common lacerations occur from blunt force trauma such as striking one's head against a coffee table. Such contact crushes the skin against an underlying bone, causing the skin to split. Crush injuries can cause trauma to surrounding tissue, and are more susceptible to infection than are wounds that have resulted from shearing forces or sharp lacerations. Check the immediate wound area. The following indications require the patient be taken to the Emergency Department.

## Wound Examination and Exploration

**Wound examination requires good lighting and should be conducted with minimal bleeding conditions.** Examination under poor lighting or when the depths of the wound are obscured by blood could result in missing embedded foreign bodies and possible internal damage.

A foreign body in a wound increases the risk of infection.

## Inspecting the Laceration for Damaged Tissue

**Wound edges that are crushed, contaminated, ragged, have flaps, or are irregular, will need Emergency Department care to be closed effectively.** Often, the surgical process removes the problematic areas creating a fresh wound that can then be closed.

## Predicting the Cosmetic Outcome

**Patients should be educated regarding their expected cosmetic outcome.** This will improve the likelihood that the result will meet their expectations. They should clearly understand that all traumatic lacerations result in some scarring. They should be told that they will have a scar but will not have the marks associated with sutures or staples. The final cosmetic appearance of the scar is generally better than suturing, but will vary according to the patients healing ability, the wound tension, and the wound location, among others.

## Wound Preparation

**Wound preparation is the key to successful closure result.** Do not focus on wound closure and neglect wound preparation. Wound preparation is intended to remove any bacteria, contaminants, or foreign bodies. It is intended to minimize bacterial levels and lessen the likelihood of wound infection. This will promote faster healing and minimize scar formation, the ultimate goal of wound management. The use of surgical/sterile gloves if available can help to reduce infection and is a standard practice in most hospitals for this reason.

## Hair Removal

**Wound preparation should begin with hair removal. Clozex Closures require at least one and one quarter (1¼) inch of exposed skin on each side of the wound to attach the anchoring ends.** When necessary, use an electric clipper, razor or scissors.

Total hair removal is not a requirement for optimal wound closure with Clozex, especially if it is sparse. However, hair removal is required if it is dense and removal of all hair is important in the area surrounding the wound where the adhesive pads will be placed. This will ensure that the wound closure is most secure with minimal hair getting stuck to the Clozex adhesive. Hair removal should provide that no hair gets into the wound itself. The hair follicles are also a significant source of bacterial contamination. Ideally, hair should be removed without traumatizing the follicles because traumatizing them may introduce bacteria into the surrounding skin and wound. Often sparse hair can be removed by clipping it with scissors. A medical professional may be necessary if the hair is very dense. Before removing any eyebrow hair, remember that this hair requires precise approximation of the divided wound edge. Removal of eyebrow hair may also result in permanent loss of hair or abnormal growth. Consequently, hair removal of the eyebrows should be avoided and should be professionally managed.

## Disinfecting the Surrounding Skin

**The skin around the wound should always be cleaned and dried. Disinfecting the skin around the wound should be conducted without contacting the wound itself.** To avoid bringing contaminated material back into the wound and to minimize inadvertent spillage of the antiseptic agent, dry gauze should be soaked in the antiseptic solution and used to scrub the wound from the wound edges outward in a circular fashion. Clinical antiseptic agents containing either an iodophor or chlorhexidine suppresses bacterial presence. Do not allow these agents into the wound. They may reduce the wound's defenses and allow the development of infection within the wound itself.

## Controlling Blood Loss

**During a skin laceration blood vessels are damaged.** The blood loss is directly related to the size of the divided vessels. Some bleeding is beneficial as there is a cleansing of the tissue. Most bleeding can be stopped by applying direct pressure to the wound area with saline-soaked clean gauze and by elevating the injured limb. In some instances, some bleeding will continue even after closing the wound. If this occurs, the site of injury should be elevated above the patient's heart to reduce the blood flow to the wound area and lessen the accumulation of these fluids in the wound spaces.

Persistent bleeding from vessels that cannot be controlled by pressure and elevation techniques may indicate more serious trauma conditions and the patient should be taken to the Emergency Department.

## Wound Irrigation

**Wound irrigation is the most important part of wound preparation.** It is an effective means of removing bacteria and contaminants. Studies have indicated that a stronger pressure washing is a more effective cleansing method and reduces infection rates compared to low pressure irrigation. Very high-pressure irrigation should be avoided as it might force bacteria into adjacent tissue.

The preferred choice of fluid to irrigate and cleanse wounds is water. The cleaner and more sterile, the better the cleansing will be. Normal saline remains the most cost-effective and readily available choice. Others include hydrogen peroxide and forms of povidine iodine. These have greater antimicrobial properties, but they can have some toxicity to healthy tissues. Sterile water (saline) is generally considered the best choice to irrigate wounds. In the field, an unopened water bottle is a good choice, especially compared to other naturally found water sources. (section continues on next page)

The volume and duration of irrigation depends on the wound characteristics. Basically, if there is a higher risk of infection, there is a greater need to clean/irrigate. Contaminated wounds with a high risk of infection require the most irrigation, and should be treated in the Emergency Department.

## Scrubbing the Laceration

**The surface skin around the wound is another primary source of bacteria that can migrate into a wound and cause an infection.** Scrubbing is the term used for cleaning all the skin surrounding a laceration and is a necessary part of wound preparation. A sterile water (saline)-soaked sponge or gauze is an effective means of removing bacteria from the skin. Scrubbing should be a firm circular motion away from the wound itself, but not too vigorous so as to inflict damage to the tissues.

## Preparing for the Clozex Application

**Select the device size(s) to match the incision shape and length.** Multiple devices can be combined in series to achieve the length needed.

Dry the skin thoroughly, prior to and during the device application as may be needed.

**See Page 6 for Step-By-Step Application Instructions.**

## Wound Care After a Clozex Closure

### Transudates

**Transudates is the term used for the small amount of straw-colored fluid that may form after the wound is closed.** The Clozex wound closure system allows these fluids to express from the wound. This is normal in the first several days of wound healing. If either large amounts of fluid, purulent (white pus) or foul-smelling fluid is seen, these are signs of infection and the patient should be instructed to see their doctor or go to the Emergency Department.

### Antibiotics

**Although all wounds are contaminated with some bacteria, only a small fraction of them develop an infection.** The best prevention for wound infections is pre-closure wound cleansing and good closure technique. However, despite good wound care, some infections still occur. Diabetes is also a risk factor for infection. Signs of wound infection include **swelling, purulent (white pus) or foul-smelling discharge, surrounding erythema (skin redness), and/or fever. If any of these occurs, the patient should see their doctor or go to the Emergency Department.**

After the Clozex closure is applied, many experts agree that the possibility of infection be reduced with the application of antibiotics or antimicrobials to the wound. There are many such creams and ointments that can be used. The method would be to gently apply the cream over and through the Clozex straps over and onto the wound edge. The need for antibiotic creams is debatable and can be based on the risk of bacterial contamination. Generally, cleaning the wound area is far more important than the use of antibiotics. Antibiotics should be used in cases where the practitioner feels there is a heightened concern for infection. One such case may be in the diabetic patient.

(section continues on next page)

There are many topical antibiotic preparations that can be used, such as bacitracin, neosporan or other triple antibiotic ointment (polymixin B, neomycin, bacitracin), orgentamicin, mupirocin (Bactroban, GlaxoSmithKline). The efficacy of these agents is debatable. It should be noted that many surgeons believe that covering a wound with a topical antibiotic agent such as Neosporin or Bacitracin creates a wet healing environment and that will reduce infection and will promote faster healing. On the other hand, many other surgeons believe that leaving lacerations exposed to air does not affect the infection rate and promotes optimal healing. Clozex closures can accommodate both options. However, in a non-sterile environment, the application of antibiotics if available, would be the preferred choice.

**The patient should be given good discharge instructions on signs of infection and follow-up, whether or not antibiotics are used.**

## Covering the Clozex Wound Area - Dressings

**Wound care after the Clozex closure is applied is improved with the application of a cover dressing.** Generally, a cover dressing provides an extra layer of protection for the wound area and it can absorb wound transudates as may be necessary. It can also be a semi-waterproof covering to allow limited water exposure, however submersion should be avoided. Optimally, the cover dressing can be removed and replaced as needed, avoiding any wear and tear to the Clozex wound closure or trauma to the wound. If a cover dressing is used, it should not be adhered directly to the Clozex device, but rather fit around it. Adherence to the device could lead to accidental removal of the Clozex closure when removing the cover dressing.

## Final Instructions to Patients

### Post Clozex Closing Wound Care Management

#### Patient should be instructed to:

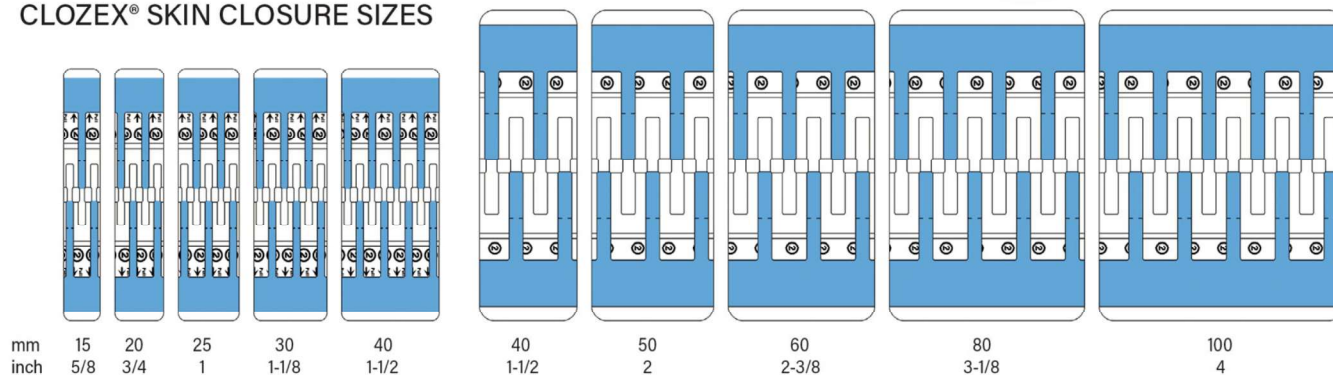
- ▶ Avoid immersing the wound in a tub or go swimming for 10 days.
- ▶ Showers are preferable to baths for 7 days, preferably with a protective cover dressing
- ▶ Avoid activities that would cause excessive sweating like vigorous exercise or work.
- ▶ Avoid stressing the wound area.
- ▶ Remove and replace cover dressings as may be necessary.
- ▶ Under normal conditions Clozex should slough off in 7 to 10 days.
- ▶ Redness, swelling, foul-smelling or purulent (white, pus) discharge, fever could indicate an infection and the patient should go to a hospital ED
- ▶ Follow-up with their doctor and any tetanus requirements that may be required.

# Clozex® Application Instructions



Clozex wound closures are numbered **1** **2** **3** and are color coded: **RED**, **WHITE** and **BLUE** to indicate the sequence of liner removal.

## CLOZEX® SKIN CLOSURE SIZES



## Clozex Application Guidance

- 1** Select the device size(s) to match the incision shape and length. Multiple devices can be combined in series to achieve the length and geometric shape needed.
- 2** Closures may be overlapped to close angled or curved wounds.
- 3** Wound edges may be adjusted/straightened with forceps prior to applying Clozex.
- 4** Clean the skin 5-7cm around the incision using a sponge moistened with isopropyl alcohol or normal saline solution, taking care to remove exudates and excessive skin oils.
- 5** Dry the skin area prior to and during device application as may be needed throughout device application.
- 6** Do not lift and reapply any portion of the device; remove it completely and reapply a new device if needed.
- 7** Once applied, the top of the Clozex device may have exposed edges that could irritate overlying pendulous tissues (e.g. breast, thigh, abdomen, axilla, etc.). To assure patient comfort, suitable cover dressing should be used over Clozex in these areas.
- 8** Do not adhere any cover dressing directly onto the Clozex device as this could result in accidental removal of Clozex device.
- 9** Provide the **Patients Care Instructions** post surgery.

### Clozex Indications for Use:

1. The closure of low-medium tension lacerations and surgical incisions.
2. As an adjunct to suture closures for higher tensioned wounds.
3. For wound reinforcement after early suture or staple removal.

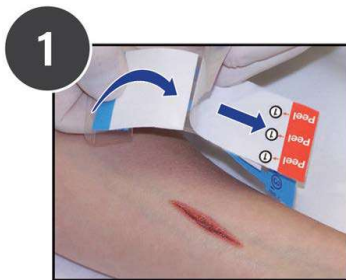
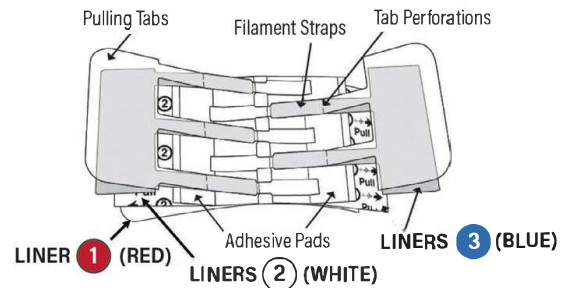
### Contraindications:

1. Do not use Clozex where good adhesion cannot be obtained such as areas with excessive amounts of wound fluids, skin oils, moisture or hair.
2. Do not use Clozex on infected areas.
3. Risks are associated with the potential dislodgement of the device and allergic reaction to the adhesive.

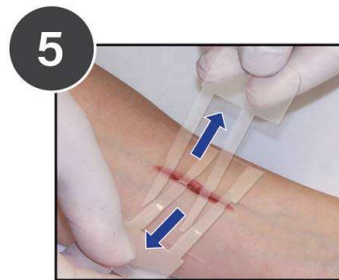
### Warnings:

1. The development of postoperative edema may cause skin shearing, skin blistering or loss of adhesion to occur.
2. As with all adhesive products applied to skin, removal can result in skin stripping.
3. As with all adhesive products applied to skin, a small percentage of individuals may experience hypopigmentation or hyperpigmentation after removal.

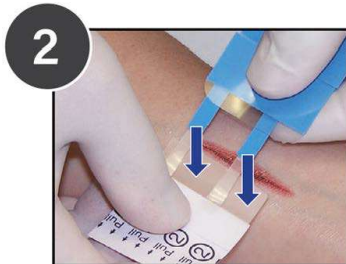
# Clozex® Step-By-Step Application



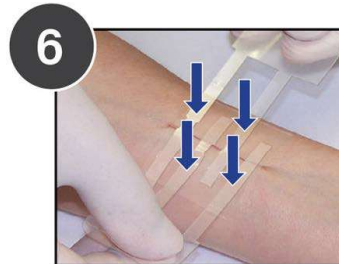
1 Remove **LINER 1 (RED)** to expose the adhesive on both clear pads of the device. Turn the device over with adhesive pads facing the skin. Pull skin closure device apart as needed to widen gap between adhesive pads.



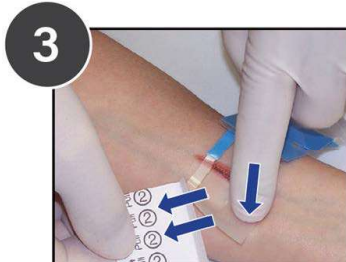5 Holding the clear pulling tabs in each hand, pull the wound edges closed uniformly all along the wound edges while gently lowering the straps.



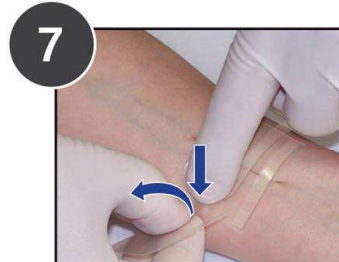2 Holding the **LINERS 2 (WHITE)**, apply each clear adhesive pad to the skin 1-2mm from each side of the wound edge. Gently press to secure each half one at a time. **APPLY PADS TO DRY SKIN ONLY.**



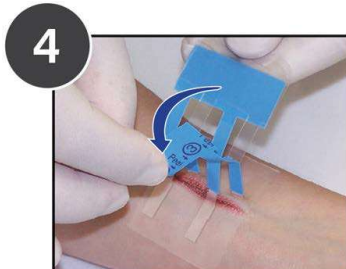
6 When the skin edges are properly aligned, lower the filament straps down onto the secured adhesive pads. Press the filament straps to secure them on the adhesive pads.



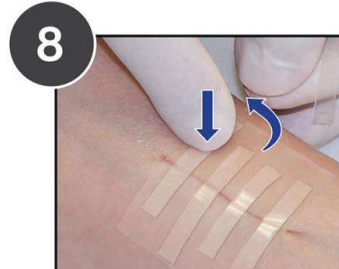
3 Gently remove **LINER 2 (WHITE)** while holding the adhered pad to the skin and gently press the pad to secure it firmly to the skin. Repeat steps 2 and 3 to apply the second pad to the second wound edge.



7 To remove the pulling ends press each adhered filament strap next to the perforation and gently twist off the end.



4 Holding the pull tabs and **LINERS 3 (BLUE)** perpendicular to the wound, peel down **LINER 3 (BLUE)** on each side exposing the filament strap adhesive. Dry the tops of the adhesive pads if needed before closing.



8 Repeat for all straps on the other side.

Clozex Medical, Inc.  
375 West Street  
W. Bridgewater, MA 02379