

Case 1

A 54 year old Caucasian female that presents with a long history of female pattern hair loss. She has had multiple treatments in the past. She has had two hair transplants, the first in 1997 consisting of 600 minigrafts and the second in 2006 consisting of ~1500 FU grafts. Both were in the female pattern area. Around 2007 she started Topical Rogaine and Oral propecia. She later added low dose oral minoxidil at 5 mg daily. Early in 2013 she had small micro pigmentation procedure done to the scalp with temporary pigment. She desired to add laser therapy to her regime.

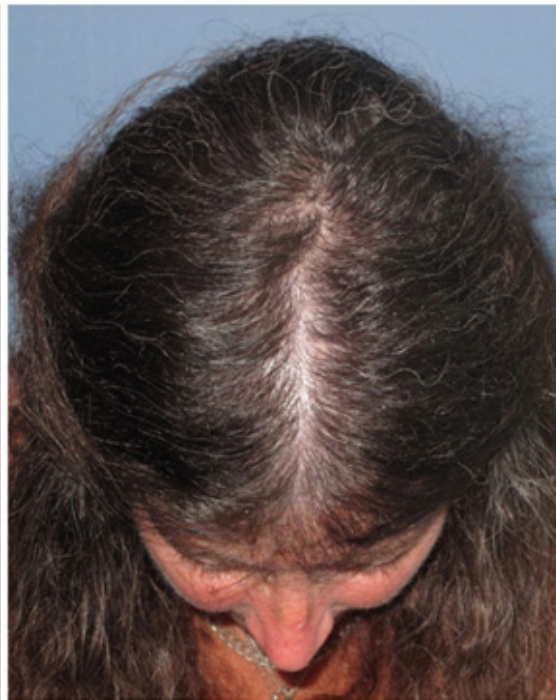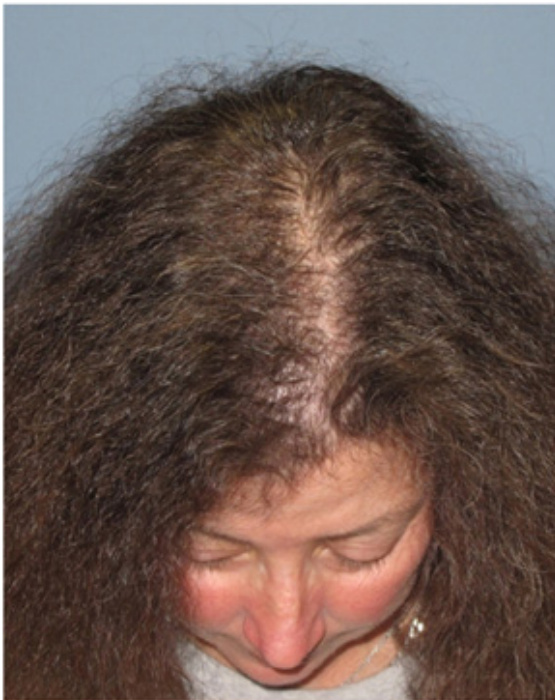Examination revealed a widened midline part line, retained frontal hairline, and decreased luster and shine of the hair overall, consistent with a diagnosis of female pattern hair loss. There was no scalp inflammation, and no evidence of infection or scarring scalp disease.

Low level laser light therapy was initiated with a LaserCap®, used 30 minutes every other day. The rest of her therapy remained the same. There was very little of the temporary micro pigment left in her scalp at the time of initiating therapy

3 Month Follow up showed improvement in her hair luster , overall thickness and the part line did not seem as thin

Before

After



Baseline	After 3 months
----------	----------------

Case 2

A 38 year old Caucasian male presented with thinning of his crown and mid scalp. No therapies had been tried. The patient denied pain or itching.

Examination revealed healthy hair and scalp but thinning in the mid scalp and crown area .No inflammation was noted.

Low level laser light therapy was initiated with a LaserCap®, used 30 minutes every other day. No topical or oral treatments were initiated. At his r follow-up visit at 3 months, the patient reported ease of use and thinks he noticed improvement but was not real sure. Examination showed increase fullness of hair in mid scalp . Figure 2 shows the comparison between the baseline and 3 month appearance.

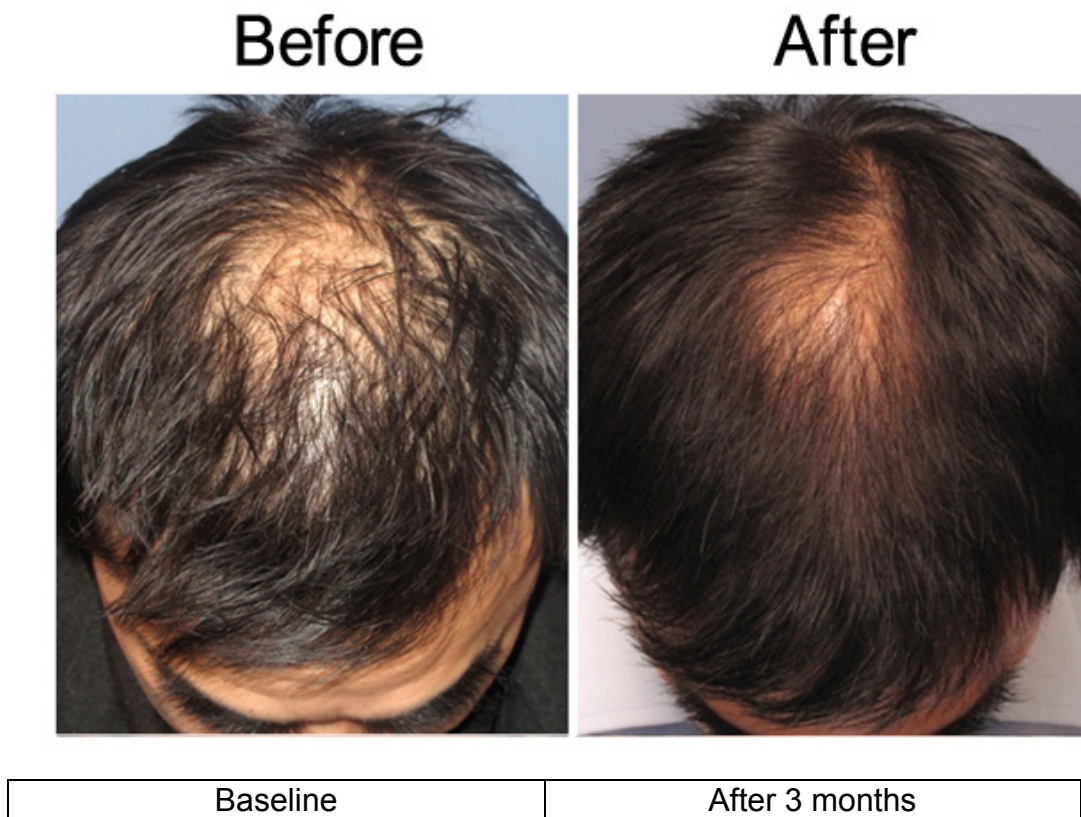


Figure 2

Case 3

A 21 year old Caucasian male presented with thinning of frontal temporal angles. No therapies had been tried. The patient denied pain or itching.

Examination revealed healthy hair and scalp but thinning in the frontal temporal angles with miniaturized hairs .No inflammation was noted.

Low level laser light therapy was initiated with a LaserCap®, used 30 minutes every other day. No topical or oral treatments were initiated.

At his follow-up visit at 3 months, the patient reported ease of use and thinks he noticed improvement but was not real sure. Examination showed possible increased fullness and decreased miniaturization in the frontal temporal area Figure 3 shows the comparison between the baseline and 3 month appearance.

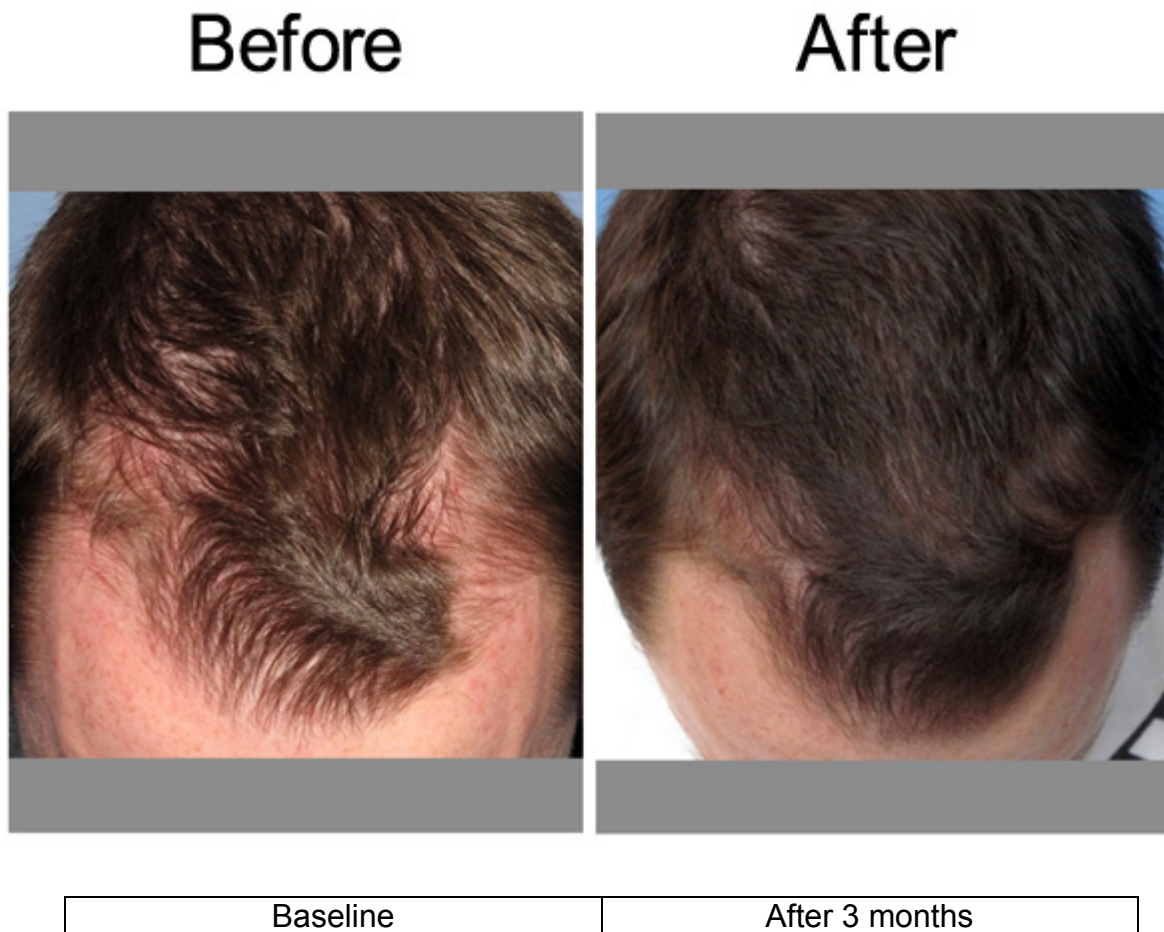

Figure 3

