

# Chinese Military Evaluation of a Portable Near-Infrared Detector of Traumatic Intracranial Hematomas

Chun-yang Liang, PhD, Colonel; Yang Yang, MD; Chun-sen Shen, MD, Colonel; Hai-jiang Wang, MD; Nai-Ming Liu, MD; Zhi-wen Wang, MD; Feng-lei Zhu, PhD; Ru-xiang Xu, PhD, Major General

**ABSTRACT** Introduction: Secondary brain injury is the main cause of mortality from traumatic brain injury (TBI). One hallmark of TBI is intracranial hemorrhage, which occurs in 40–50% of severe TBI cases. Early identification of intracranial hematomas in TBI patients allows early surgical evacuation and can reduce the case fatality rate of TBI. As pre-hospital care is the weakest part of Chinese emergency care, there is an urgent need for a capability to detect brain hematomas early. In China, in addition to preventing injuries and diseases in military staff and in enhancing the military armed forces during war, military medicine participates in actions such as emergency public health crises, natural disasters, emerging conflicts, and anti-terrorist campaigns during peacetime. The purpose of this observational study is to evaluate in the Chinese military general hospital the performance of a near-infrared (NIR)-based portable device, developed for US Military, in the detection of traumatic intracranial hematomas. The endpoint of the study was a description of the test characteristics (sensitivity, specificity, and positive and negative predictive values [NPV]) of the portable NIR-based device in identification of hematomas within its detection limits (volume >3.5 mL and depth <2.5 cm) compared with computed tomography (CT) scans as the gold standard. Materials and Methods: The Infrascanner Model 2000 NIR device (InfraScan, Inc., Philadelphia, PA, USA) was used for hematoma detection in patients sustaining TBI. Data were collected in the People's Liberation Army General Hospital in Beijing using the NIR device at the time of CT scans, which were performed to evaluate suspected TBI. One hundred and twenty seven patients were screened, and 102 patients were included in the per protocol population. Of the 102 patients, 24 were determined by CT scan to have intracranial hemorrhage. The CT scans were read by an independent neuroradiologist who was blinded to the NIR measurements. Results: The NIR device demonstrated sensitivity of 100% (95% confidence intervals [CI] 82.8–100%) and specificity of 93.6% (95%CI 85–97.6%) in detecting intracranial hematomas larger than 3.5 mL in volume and that were less than 2.5 cm from the surface of the brain. Blood contained within scalp hematomas was found to be a major cause of false-positive results with this technology. Conclusion: The study showed that the Infrascanner is a suitable portable device in Chinese population for detecting preoperative intracranial hematomas in remote locations, emergency rooms, and intensive care units. It could aid military medics, physicians, and hospital staff, permitting better triage decisions, earlier treatment, and reducing secondary brain injury caused by acute and delayed hematomas.

## INTRODUCTION

Throughout China's military relationship with the West, one aspect of the connection that has consistently been well received by both sides is medicine. Given the historical respect and converging interests in Chinese and American civil and military medicine, this may serve as *guānxi* (literally “relationship, connection”), a Chinese concept that refers to a common tie that functions to bind relationships together and is the basis for much societal interaction in China.<sup>1</sup> In China, military medicine plays a key role in supporting and maintaining health, preventing injuries and diseases in military personnel, and enhancing the military armed forces during war. Additionally, military medicine participates in actions such as emergency public health crises, natural disasters, emerging conflicts, and anti-terrorist campaigns during peacetime.<sup>2</sup>

Trauma has become the fourth leading cause of death, in China, after heart disease, cancer, and cerebrovascular accidents, and it is the leading cause of death in adults under the age of 40 yr. Among various traumas, traumatic brain injury (TBI) has the highest mortality and the most serious consequences and is the most difficult to treat. It has been reported that patients who die of TBI account for 87% of all trauma deaths. The proportion of severe TBI in China is much higher than that in other countries (20% vs. 10%).<sup>3</sup> TBI is frequently referred to as the “silent epidemic” because complications from TBI, such as cognitive, sensory, or emotional impairments, may not be readily apparent. The loss of human potential, long-term impairments, and disabilities associated with TBI has a tremendous impact on Chinese society. In addition, awareness about TBI among the general public is limited.<sup>4</sup>

An estimated three to four million people experience TBI each year in China<sup>5</sup> or an annual rate of 340–450 per 100,000 people.<sup>6</sup> Incidence of moderate-to-severe TBI in the rural population was almost 2.5 times greater than in the urban population. Secondary brain injury, which occurs in minutes to days following primary injury, is the main cause of TBI mortality. Early identification, prevention, and correction of these events

Affiliated Bayi Brain Hospital, The P.L.A Army General Hospital, Beijing, 100700, China.

doi: 10.1093/milmed/usx088

© Association of Military Surgeons of the United States 2018. All rights reserved. For permissions, please e-mail: journals.permissions@oup.com.

in the pre-hospital setting can lower the risk of secondary brain injury and reduce the case fatality rate of TBI. For patients with moderate-to-severe TBI in particular, diagnosis within the first (“golden”) hour of the traumatic event is critical. As pre-hospital care is the weakest part of Chinese emergency care, suboptimal practices in TBI management may exist in pre-hospital settings.<sup>3</sup>

One hallmark pathological process in TBI is intracranial hemorrhage, which occurs in 40–50% of severe head trauma cases.<sup>7</sup> Early diagnosis and surgical evacuation of intracranial hematomas are fundamental management principles for traumatic hematomas.<sup>8</sup> Early identification of intracranial hematomas in TBI patients allows early surgical evacuation, which can be an important determinant of outcome.

A practical adjunct to this goal of early identification of intracranial hematomas in the field and emergency center may be the use of a portable near-infrared (NIR) technology. A NIR-based, handheld medical triage tool (Infrascanner by InfraScan, Inc., Philadelphia, PA, USA) has been developed, with support from the US Navy and Marines, to screen for brain hematomas at the site of injury.<sup>9</sup> For patients with traumatic brain hematomas, a rapid diagnosis, followed by immediate evacuation to a location, which has both computed tomography (CT) and neurosurgical intervention capability, is paramount to maximizing survivability and minimizing irreversible neurological impairment. Furthermore, especially with mild TBI, automatic patient evacuation to a trauma center is not practical, as it can lead to substantial resource wastes and unnecessary risk to military helicopter crews.

In laboratory tests with phantom models of intracranial hematomas, the smallest volume of blood that can be detected with the device was found to be 3.5 mL, and the hematoma must be within 2.5 cm of the brain surface to be detected. For TBI, the vast majority of the hematomas involve the surface of the brain, within 2.5 cm of the brain surface. The detection threshold of 3.5 mL is almost an order of magnitude smaller than 25 mL hematomas that warrant surgical intervention.

In a multicenter study (431 patients) conducted with a prototype Infrascanner, sensitivity for detection of intracranial hematomas was 88% as compared with CT scan readings.<sup>10</sup> Specificity in the per protocol population was 90.7%. The type of hematoma could not be determined with certainty in this study; however, it was possible to detect the presence of any type of traumatic intracranial hematomas. Leon-Carrion et al<sup>11</sup> studied the use of the Infrascanner in 35 patients with intracranial hematomas and found an overall sensitivity of 89.5% and specificity of 81.2%, as compared with CT. Bressan et al<sup>12</sup> evaluated 110 children at intermediate or high risk for intracranial injury. There was only one brain hematoma case in this group (it was successfully detected). The specificity in this test was 93%. The use of Infrascanner would have led to the avoidance of 10 CT scans, reducing the CT scan rate by 58.8%. Tyzo et al<sup>13</sup> evaluated 94 children with mild TBI. The sensitivity in this test was 86.7% and specificity was 90%. The

results of this study led to the adoption of the Infrascanner as part of the standard of pediatric care in Poland.<sup>14</sup>

As part of US–Chinese Military Medicine cooperation, the purpose of this clinical study is to evaluate in the central Chinese military hospital the performance of this NIR-based portable device, developed for US Military, in the detection of traumatic intracranial hematomas. The high incidence of TBI, and especially of severe TBI in China, coupled with suboptimal pre-hospital care, increases the special need in China for pre-hospital brain hematoma detection ability. The different prevalence of TBI patients, coupled with Chinese military hospital environment, requires verification of previous data in Chinese patient population and in our specific working conditions. Therefore, we believe that the first-hand triage reliability evaluation of the Infrascanner in Chinese patients, admitted to a military trauma center, is necessary. The endpoint of the study was a description of the test characteristics (sensitivity, specificity, positive, and NPV) of the portable NIR-based device in identification of hematomas within its detection limits (volume > 3.5 mL and depth < 2.5 cm) compared with CT scan as the gold standard.

## MATERIALS AND METHODS

### *Theoretical Basis for Detection of Hematomas with NIR Technology*

Due to its unique light-absorbing properties, hemoglobin molecules within tissue have the highest absorption rate in the NIR range (700–900 nm).<sup>15,16</sup> The principle used in identifying intracranial hematomas with NIR is that extravascular blood absorbs NIR light more than intravascular blood. This is because there is a greater (usually 10-fold) concentration of hemoglobin in an acute hematoma than in normal brain tissue where blood is contained within vessels. The NIR-based device, Infrascanner, compares light absorption in both the left and the right sides of the brain in four different areas. The absorbance of NIR light is greater (and therefore the reflected light less) on the side of the brain containing a hematoma than on the uninjured side. With specified wavelength ranges, optical light source(s) or emitter(s) and a photodetector are placed at a distance, which allows proper NIR absorption measurements in a desired volume of tissue. The used wavelength of 805 nm, the isosbestic point of hemoglobin, is sensitive only to blood volume, not to oxygen saturation in the blood.

The device is placed successively in the left and right frontal, temporal, parietal, and occipital areas of the head in a pre-defined sequence and the absorbance of light is recorded (see Fig. 1). The difference in optical density ( $\Delta OD$ ) in each of the four symmetrical areas of the head is calculated on a pair-wise basis using the following formula:

$$\Delta OD = \log_{10} \left( \frac{I_L}{I_R} \right)$$

where  $I_L$  is the intensity of reflected light on the left side of the head and  $I_R$  is the intensity of reflected light on the right side.

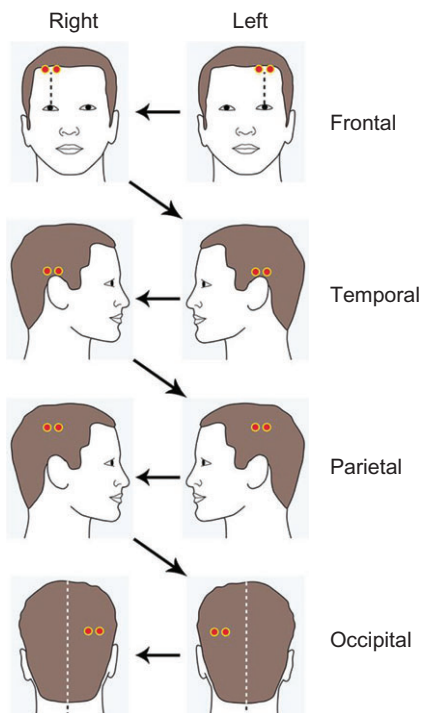
Intracranial hematoma detection was established when a  $\Delta OD > 0.2$  units occurred in a particular pair of bilateral measurements. When a measurement indicated a difference greater than  $\pm 0.2$  OD, the measurement pair was repeated twice to verify the presence of a hematoma. A  $\Delta OD \leq 0.2$  units was considered a negative exam. The 0.2 cutoff for the Infrascanner was set following a previous study on hematoma detection using NIR.<sup>17</sup>

### Study Design

The study was a single-center observational study to test the performance of the portable NIR device to screen for intracranial hemorrhage, comparing the findings of the NIR exam to those of the admission CT scan.

### Selection of Participants

Patients of any age were eligible for the study if they were undergoing a CT scan within 12 h of a blunt or penetrating head injury between August 2015 and December 2016. Trained operators were available during regular business hours. All eligible patients were enrolled during those time periods. The criteria for obtaining a CT scan were based on the standard of care. The non-contrast CT was performed according to standard methods.



**FIGURE 1.** Measurement locations and data acquisition sequence for Infrascanner in patients with suspected brain injury. The two dots for each measurement location represent the two optical fibers placed on the head (one for the laser light source and the other for the optical detector).

### Methods of Measurement

The Infrascanner Model 2000 NIR device is used for hematoma detection in patients sustaining TBI. The NIR device consists of two components: a sensor and a charging cradle. The sensor includes an 808 nm diode laser and a silicon detector. The sensor delivers NIR light to the tissue and receives it after it has interacted with the tissue via fiber optics mounted in a plastic, single patient use disposable shield. The fiber optics are designed so that they can be maneuvered between hair roots to minimize the interference from hair without the need to shave it (see Fig. 2). The detected signal is then digitized and analyzed by a single-board computer in the scanner. The computer processes the data further and displays the results on its screen.

Within 30 min before or after the CT scan was performed for clinical indications, an operator independently performed a standardized examination with the portable NIR device. At each location, the actual measurement of the portable NIR device takes up to 10 s. The whole head scan takes less than 3 min. Operators were identified and trained both about how to use the NIR equipment and about how to place the device in the appropriate locations for the standardized examination. Only trained operators collected data from patients in this study.

With each examination, the  $\Delta OD$  for each of the four brain regions was recorded, and the  $\Delta OD_{max}$ , defined as the



**FIGURE 2.** Portable NIR detector of intracranial hemorrhage, the Infrascanner: (a) The Infrascanner kit in a ruggedized carry case. (b) The Infrascanner with disposable fiber optic shield in hand and placed on a head.

greatest absolute value for  $\Delta OD$  among the various regions examined, was recorded. The presence or absence of a hematoma was determined by comparing the  $\Delta OD_{max}$  measurement to a pre-defined threshold of 0.2.

The endpoint of the study was a description of the test characteristics (sensitivity, specificity, positive, and NPV) of the portable NIR-based device in the identification of hematomas within its detection limits (volume >3.5 mL and depth <2.5 cm) when compared with CT scan results as the gold standard.

**Primary Data Analysis**

The analyses of the performance of the portable NIR-based device were conducted using a “per protocol” population. Patients were excluded from the analysis if they had large scalp lacerations or blood on the scalp over the scan area or not meeting the inclusion criteria. Patients were also excluded from the analysis when the NIR device scan was not completed according to the scanning protocol.

**RESULTS**

**Characteristics of the Study Subjects**

One hundred and twenty seven patients were screened for participation in the study. The per protocol population, as defined in the methods section, included 102 patients. The protocol violations that excluded the other 25 patients from the analysis were blood or lacerations on the scalp over the scan area ( $n = 3$ ), not meeting the inclusion criteria ( $n = 2$ ), and not following the scanning protocol ( $n = 20$ ). In the initial phase of the study, with multiple system operators, the team faced training challenge and 20 patients were scanned not according to the protocol (and hence were excluded from the analysis). Following interaction with the system manufacturer, the software of the system was upgraded to the new “Guided” mode. This mode was developed based on feedback from US military personnel and changed the system user interface to step-by-step scanning instructions. The new software also follows the scanning sequence automatically. There were no further scanning protocol violations after switching to the “Guided” mode software.

Mostly adults were represented in this study with a range in age from 9 yr to 86 yr (mean of 41 yr). Out of 102 patients, males were evaluated for suspected TBI more often (57%) than females (43%). The incidence of female TBI in China (44%)<sup>18</sup> is higher than in the West and indicates the higher equity and integration of women into the workforce in China. The unique demographic aspect of this study population was that it included 100% Han Chinese. Characteristics that might affect performance of an optical method, such as skin and hair color and hair thickness, were collected for the patient population. The Glasgow Coma Scale score was also collected on admission (Table I). The mechanism of brain injury, from most frequent to least frequent, was assaults, falls, accidents (including motorized and non-motorized vehicle accidents), and unknown. In the per protocol group, there were two

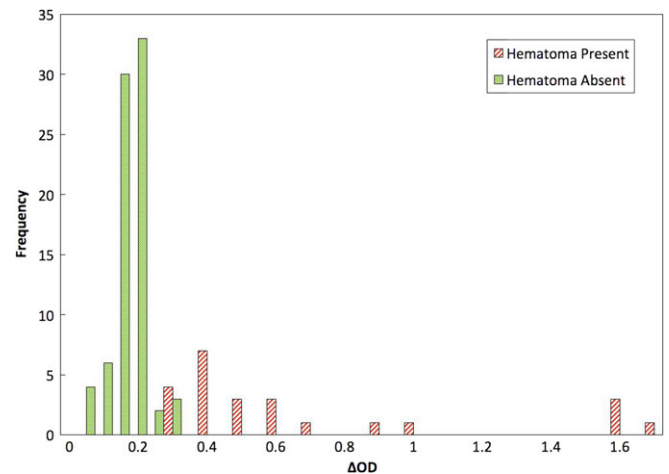
subdural hematomas, two epidural hematomas, and 20 intracerebral hematomas for a total of 24 patients with intracranial hematomas (prevalence of 23.5%) following an acute TBI. The remaining 78 patients did not have intracranial hemorrhage.

**Procedure**

This study was performed with patients admitted to the Department of Neurosurgery, General Hospital of the People’s Liberation Army, Beijing, China. The Hospital Institutional Review Board approved this study and all procedures were in accordance with the Declaration of Helsinki guidelines.

**TABLE I.** Demographic and Clinical Characteristics of Study Subjects ( $n = 102$ )

|                | Characteristic | Subjects   |
|----------------|----------------|------------|
| Age (years)    | Range          | 9–86       |
|                | Mean           | 41         |
| Sex            | Male           | 58 (57%)   |
|                | Female         | 44 (43%)   |
| Race           | Han            | 102 (100%) |
| Skin color     | Light          | 37 (36%)   |
|                | Dark           | 65 (64%)   |
| Hair color     | Black          | 65 (64%)   |
|                | Brown          | 14 (14%)   |
| Hair thickness | Light          | 21 (20%)   |
|                | None (bald)    | 2 (2%)     |
|                | Thick          | 7 (7%)     |
|                | Normal         | 67 (66%)   |
| GCS            | Thin           | 26 (25%)   |
|                | None (bald)    | 2 (2%)     |
|                | 3–8            | 8 (8%)     |
|                | 9–12           | 3 (3%)     |
|                | 13–15          | 91 (89%)   |



**FIGURE 3.** Distribution of maximal difference in optical density ( $\Delta OD_{max}$ ) measured by the Infrascanner for patients with intracranial hemorrhage present ( $n = 24$ ) and intracranial hemorrhage absent ( $n = 78$ ).

**TABLE II.** NIR Device Performance

| Epidural, Subdural, and Intracerebral Hematomas, Volume >3.5 mL and Distance <2.5 cm from Brain Surface (102 Patients, 24 with Intracranial Hematomas Within NIR Detection Limits) |                     |                |                                   |
|--|---------------------|----------------|-----------------------------------|
| Specificity (95%CI)  | Sensitivity (95%CI) | NPV (95%CI)    | Positive Predictive Value (95%CI) |
| 93.6 (85–97.6)   | 100 (82.8–100)      | 100 (93.8–100) | 82.8 (63.5–93.5)                  |

95%CI = Exact 95% confidence intervals.

### Main Results

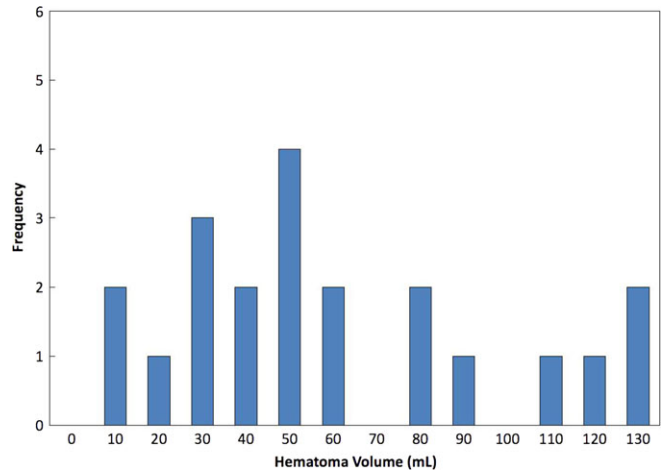
The distribution of  $\Delta OD_{\max}$  values for all 102 per protocol patients is illustrated in Figure 3, separated by whether or not intracranial hemorrhage was identified on the CT scan. The  $\Delta OD_{\max}$  for the 78 cases where no intracranial hemorrhage was identified on the CT scan ranged from 0.01 to 0.29, but 93.6% of the cases were  $\leq 0.20$ , which was predefined as the threshold for identification of intracranial hemorrhage. All the 24 cases, where intracranial hemorrhage of size larger than the detection ability of the Infrascanner (3.5 mL) had a  $\Delta OD_{\max}$  greater than the predefined threshold of 0.2. Table II shows the full performance data for all per protocol cases. Positive predictive value was 82.8% and NPV was 100%.

Several limitations for identifying intracranial hematomas with NIR were observed in this study. First, the size, type, and location of the hematoma cannot be as precisely determined as with a CT scan. Second, the NIR examination is sensitive to injury of the scalp. Blood contained within a scalp hematoma can also alter the OD and cause a false-positive result with this technology. The presence of a scalp laceration or hematoma was an exclusion criterion for this study. Despite the effort to exclude open scalp injury, subgaleal hematomas are less obvious and can contribute to false positives. Five such cases were observed in this study, out of 78 patients without intracranial hematomas.

### DISCUSSION

The most significant result of this study is that the handheld NIR Infrascanner demonstrates excellent sensitivity and specificity in detecting intra- and extra-axial traumatic hematomas and, even more importantly, it is able to detect reliably small hematomas (<25 mL) within the first 12 h following injury. Data show that the Infrascanner demonstrated high sensitivity (100%) and specificity (93.6%) in detecting traumatic intracranial hematomas >3.5 mL in volume and <2.5 cm from the surface of the brain. Its on-site capacity to identify patients that have suffered an intracranial hematoma should be considered as very high.

This study confirms in Chinese patients admitted to a military trauma center the findings of previous investigations demonstrating that NIR technology can be reliably used to screen for the presence of intracranial blood from a simple examination of the difference in optical density between the



**FIGURE 4.** Distribution of the blood volume of the 24 intracranial hematomas observed in this study.

area involved in the hemorrhage and the uninvolved site on the opposite side of the head.<sup>10–13,17</sup>

The sensitivity for identifying intracranial hematomas in the studies by Robertson et al<sup>10</sup> and Leon-Carrion et al<sup>11</sup> was 88% and 89.5%, respectively. Robertson noted that for patients with larger bleeds, the sensitivity was higher. The TBI patients admitted to the General Military Hospital are usually the more severe cases and therefore had substantially higher prevalence of larger brain hematomas. Comparing Figure 3 in Robertson et al<sup>10</sup> with Figure 4 here, showing the distribution of the volume of the intracranial hematomas observed, reveals that in this study, there was a substantially higher rate of large hematomas than in the Robertson's study. The higher prevalence of larger hematomas provides an explanation for the higher sensitivity we observed in this study.

The specificity in the studies by Robertson et al and Leon-Carrion et al was 90.7% and 81.2%, respectively. Unlike previous studies, the Infrascanner used in this study included the new "Guided" mode. This new user interface helps the operator to follow the scanning protocol and assists in performing the measurements correctly. The use of this software helped increase scanning protocol compliance and reduced user errors. Rigorous operator training coupled with the use of the Guided Mode contributed to the higher specificity observed in this study, as compared with previous research.

The Infrascanner's high specificity and high NPV suggest that the device could supplement clinical information, such as neurological status, mechanism of injury, and hemodynamic stability, all of which are used in the field to triage patients to a trauma center and in the emergency unit to determine the urgency and/or need for subsequent imaging studies. A positive NIR exam could give higher priority for evacuation or imaging, even in an otherwise low-risk patient, particularly in cases where the detection is made before hospitalization in places or situations where CT scans are not available or in cases of mass TBI casualties, such as natural or man-made disasters. It is a simple and quick test to perform. NIR technology uses non-ionizing and safe light and is especially suitable for use in radiation-sensitive patient groups such as children and pregnant women.

## CONCLUSIONS

In conclusion, the study showed that the Infrascanner is a suitable portable triage device in Chinese population for detecting preoperative intracranial hematomas in remote locations, emergency rooms, and intensive care units. It could aid military medics, physicians, and hospital staff, permitting better triage decisions, earlier treatment, and reducing secondary brain injury caused by acute and delayed hematomas.

## FUNDING

The study was supported by a grant from Beijing Scientific Association (project number: Z171100001017165).

## REFERENCES

1. Chambers JA: The rise of Chinese military medicine: opportunity for mercy ship, not gunboat, diplomacy. *Mil Med* 2011; 176(9): 1043.
2. Fu X: Military medicine in China: old topic, new concept. *Mil Med Res* 2014; 1: 2.
3. Kou K, Hou X, Sun JD, Chu K: Current pre-hospital traumatic brain injury management in China. *World J Emerg Med* 2014; 5(4): 245–54.
4. Li Y, Gu J, Zhou J, et al: The epidemiology of traumatic brain injury in civilian inpatients of Chinese Military Hospitals, 2001–2007. *Brain Injury* 2015; 29: 7–8. 981–8.
5. Liu B: Current status and development of traumatic brain injury treatments in China. *Chin J Traumatol* 2015; 18: 135–6.
6. Zhao Y-D, Wang W: Neurosurgical trauma in People's Republic of China. *World J Surg* 2001; V25(9): 1202–4.
7. Foulkes M, Eisenberg HM, Jane JA, Marmarou A, Marshall LF: The Traumatic Coma Data Bank: design, methods, and baseline characteristics. *J Neurosurg* 1991; 75(suppl): S8–13.
8. Bullock MR, Chesnut R, Ghajar J, et al: Guidelines for the surgical management of traumatic brain injury. *Neurosurgery* 2006; 58: S2–1-S2-60.
9. Ayaz H, Ben Dor B, Solt D, Onaral B: Infrascanner: cost effective, mobile medical imaging system for detecting hematomas. *J Med Devices* 2011; 5: 027540. doi:10.1115/1.3591407.
10. Robertson C, Zager E, Narayan R, et al: Clinical evaluation of a portable near-infrared device for detection of traumatic intracranial hematomas. *J Neurotrauma* 2010; 27(9): 1597–604.
11. Leon-Carrion J, Dominguez-Roldan JM, Leon-Dominguez U, Murillo-Cabezas F: The infrascanner, a handheld device for screening in situ for the presence of brain haematomas. *Brain Injury* 2010; 24(10): 1193–201.
12. Bressan S, Daverio M, Martinolli F, et al: The use of handheld near-infrared device (Infrascanner) for detecting intracranial haemorrhages in children with minor head injury. *Childs Nerv Syst* 2014; 30(3): 477–84.
13. Tyzo B, Trojanowski T, Szczepanek D, Rola R: Algorithm of initial management of mild head injury using the portable near-infrared spectroscope. *Neurol Praktyczna* 2014; 2: 13–20.
14. Skotnicka-Klonowicz G, Godziński J, Hermanowicz A, et al: Management of minor to moderate head trauma in children – guidelines of the Polish Association of Pediatric Surgeons. *Standardy Medyczne/ Problemy Chirurgii Dziecięcej* 2014; 4: 42–50.
15. Cope M: The Development of a Near-Infrared Spectroscopy System and Its Application for Noninvasive Monitoring of Cerebral Blood and Tissue Oxygenation in the Newborn Infant. Ph.D. Thesis (1991), Univ. College London: London.
16. Strangman G, Boas DA, Sutton JP: Non-invasive neuroimaging using near-infrared light. *Biol Psychiatry* 2002; 52: 679–93.
17. Robertson CS, Gopinath SP, Chance B: Use of near infrared spectroscopy to identify traumatic intracranial hematomas. *J Biomed Opt* 1997; 2: 31–41.
18. Wang C-C, Schoenberg BS, Li S-C, Yang Y-C, Cheng X-M, Bolis CL: Brain injury due to head trauma: epidemiology in urban areas of the People's Republic of China. *Arch Neurol* 1986; 43: 570–2.