

## **Synovium Gastrosafe Study**

An investigation into the efficacy of a commercially available gastric supplement for the treatment and prevention of Equine Gastric Ulcer Syndrome (EGUS)

**Credit: E. Hatton, C.E. Hale, and A.J. Hemmings**

*Writtle College, Writtle, Chelmsford, Essex, CM1 3RR. Royal Agricultural College, Cirencester, Gloucestershire, GL7 6JS. E: [catherine.hale@writtle.ac.uk](mailto:catherine.hale@writtle.ac.uk)*

### **Conclusion**

Equine Gastric Ulcer Syndrome (EGUS) has been found to be widely prevalent in both racing, and non-racing horses (Murray et al., 1989; Hartmann and Frankeny, 2003; Nieto et al., 2004; Chameroy et al., 2006).

Traditional treatments often necessitate drug therapy (Andrews et al., 1999), which may be expensive, and competition regulations could inhibit their use.

Gastrosafe TM is a commercially available nutritional supplement, intended for daily feeding to horses with gastric disturbances. This trial investigated the efficacy of the product in the treatment of EGUS and found that horses supplemented with Gastrosafe TM for six weeks showed significant ( $P < 0.05$ ) reduction in their overall ulcer score. It can therefore be concluded that Gastrosafe has effective results in reducing the severity of EGUS in affected horses.

### **Introduction**

With the development of new methods of gastroscopy in recent years, Equine Gastric Ulcer Syndrome (EGUS) has become widely diagnosed in many animals (Hartmann and Frankeny, 2003; Nieto et al., 2004; Chameroy et al., 2006). It has been suggested that the frequency of the condition amongst racing Thoroughbreds may be as high as 90% (Murray et al., 1989), with gastric lesions being identified in 100% of racehorses, in some instances (Murray et al., 1996). In non-racing horses, 51% showing signs of gastric disturbance were found to be affected, with a further 37% of horses not showing signs displaying a significant number of lesions, enough to be classed as suffering from EGUS (Bullimore et al., 2001).

Clinical signs of the disease include weight loss, diarrhoea, decreased appetite, behavioural changes, decreased performance and colic (Murray et al., 1989; Murray et al., 1996; McClure et al., 1999; Vatisas et al., 1999; Bullimore et al., 2001; Nieto et al., 2004). Purposed reasons for the development of EGUS are wide ranging. Bullimore et al., (2001) suggests that ulceration arises from imbalances between defensive mechanisms and aggressive factors within the stomach.

It is often assumed that excess acid and pepsin secretion in the glandular region of the stomach may be to blame. However, work in human sufferers of gastric ulceration have shown us that many patients display near to normal acid secretion (Grossman et al., 1963). It is therefore highlighted that defensive mechanisms within the stomach are just as vital in the prevention of ulceration. In the glandular region of the stomach, a mucus layer is secreted to protect against autodigestion and bacterial infection (Bullimore et al., 2001). It has been found that bicarbonate ions are secreted into the mucus allowing the surface pH to be maintained near neutral, even when luminal pH is below 2 (Quigley and Turnberg, TM 1987). Mucus also contains the glycoprotein mucin. It is thought that abnormal variations and molecular characteristics of mucins can compromise permeability of mucus gels, and therefore mucosal defence (Bullimore et al., 2001). Indeed, in human patients, gastric ulceration has been associated with abnormal mucin gene expression and glycosylation (Jass and Robertson, 1994; Filipe and Ramachandra, 1995).



Although it is acknowledged that the majority of EGUS lesions are found to be present in the non-glandular region of the equine stomach (hindgut), it has recently been noted that a gene homologous to the human MUC5 is expressed within the equine stomach in both glandular and non-glandular regions (Bullimore et al., 2001).

MUC5 AC is responsible for the production and expression of neutral mucins, and its presence in both regions of the stomach suggests some mucosal defence in the proximal stomach areas. Therefore, abnormal production of the gene may lead to reduced defence, as highlighted in humans (Bullimore et al., 2001).

Other causes of ulceration are thought to be due to excessive acid build up (Jones 2002), which could lead to unnatural movement of acid in the non-glandular (hindgut) regions. This may be due to mechanical blockage of the stomach. However, this situation may be compounded in meal-fed horses given restricted access to forage, as stomach secretions are continuous, even when the stomach is empty (Frape, 1998). Furthermore, restricted forage intake is also noted to reduce salivary bicarbonate production, and thus reduce the overall buffering capacity within the proximal end of the stomach (Frape, 1998).

Treatment of EGUS is primarily with pharmacological agents that either act as H2 blockers or as acid pump inhibitors (Andrews et al., 1999). Nutritional supplements, that have proven their efficacy in scientific trials, could potentially be used in addition to veterinary therapy following an initial course of drug treatment, or during periods where conventional drug treatment must be withheld in order to avoid contravening doping regulations for clean sport. However, it is the prevention of this disease, through management and supplementation of gastric treatments, which horse owners could use to ultimately reduce the high occurrence of EGUS.

The aim of this study was to investigate the efficacy of a commercially available gastric supplement, purported to increase mucin production and combine with natural bicarbonate production to produce the defensive gels within the stomach.

## **Materials and Methods**

26 National Hunt Thoroughbred Racehorses were used in the study. All were aged between 4 and 10 years, and all resided on the same yard. All horses were maintained on their original diet, and all horses remained in their normal training routine. Horses were housed in stables and were each turned out to grass for 1 hour per day. No additional supplements or conflicting medical treatments were given throughout the duration of the trial.

### **Animal Recruitment to the Trial**

All animals used in the trial were routinely scoped for veterinary purposes. All horses recruited to the trial were to be scoped regardless of the trial, at the request of the trainer. Horses were initially scoped and divided into three categories depending on their ulcer score; Clear (ulcer score 0), n = 5, Mild to Moderate (ulcer score 1-2), n = 14 and Severe ulceration (ulcer score 3-4), n = 7, within which horses were further divided into supplemented (n = 14) and non-supplemented (n = 12) groups. Each group (treatment and control), were blocked to allow equal numbers of each ulcer score to be allocated to either treatment or control. Blocked animals were then assigned to treatment groups randomly. See table 1.

**TABLE 1** - shows assignment of horses to treatments. Total numbers in each group were: Clear – Treatment, n = 3, Control, n = 2; Mild to Moderate – Treatment, n = 7, Control, n = 7; Severe – Treatment, n = 4, Control, n = 3.

Horse Number	Ulcer Score	Treatment (T) or Control (C)
1	0	T
2	0	C
3	0	T
4	0	T
5	0	C
6	1	C
7	1	C
8	1	T
9	1	T
10	1	T
11	1	C
12	1	T
13	1	C
14	2	T
14	2	C
16	2	T
17	2	C
18	2	C
19	2	T
20	3	T
21	3	C
22	3	T
23	3	T
24	4	C
25	4	T
26	4	C

### **Gastroscopy**

Gastroscopic examination was performed after a fasting period of 20 hours and water was withheld for 4 hours prior to scoping. The examination was performed at the request of the owner, by a registered veterinary practitioner. Examination was carried out using a video Med – V.10.300, CCD Cam 3 endoscope with Xenon XL – M180 light source. The scope measures in at 3 meters in length, with an external diameter of 9.8 mm. Each individual horse’s gastroscopy was recorded on to a DVD for later consultation. A panel of veterinarians scored each horse and an average score was then given; the scoring system used is outlined in Table 2.

**TABLE 2 – Ulcer Scoring System (as proposed by EGUS Council)**

Number	Score Description
0	Epithelium is intact throughout; no hyperemia, no hyperkeratosis- normal
1	Mucosa is intact but there are areas of hyperemia and/or hyperkeratosis (thickening)
2	Small, single, or multi-focal erosions or ulcers
3	Large, single, or multi-focal ulcers, or extensive erosions/superficial lesions
4	Extensive ulcers, with areas of deep submucosal penetration

Horses were supplemented for a period of 6 weeks. All horses used in the trial were due to be re-scoped as part of the normal management after this time, therefore the trial was restricted to this length so as not to subject animals to unnecessary endoscopic procedures. Ulceration was then assessed as before. Nine horses were removed from the trial due to unrelated reasons that resulted in the cessation of training, this resulted in overall group numbers being – treatment n = 11 and control n = 6.

### **Supplementation**

The commercially available supplement, Gastrosafe was administered to treated horses at recommended levels of 100g/day, split between three feeds, for a period of 6 weeks. Gastrosafe is marketed as a gastric supplement intended for daily feeding to horses prone to gastric disturbances. It is purported that Gastrosafe will assist in maintaining optimum gut health and function, allowing maximum utilization of feed.

### **Compositional Analysis of Supplement Per 100g**

Calcium Carbonate	20,000 mg
Magnesium Hydroxide	10,000 mg
Seaweed Extract (from Laminaria Hyperborea)	10,000 mg
Fructo-oligosaccharides	10,000 mg
Glutamine	3,800 mg
Threonine	4,720 mg

### **Justification for Ingredient Inclusion**

\*Fructo-oligosaccharides (FOS) have recently been classified as prebiotics (Mikkelsen and Jensen, 2004); substances that are recognised to stimulate growth of desirable bacteria (Kapiki et al., 2007), which can result in a positive symbiotic relationship between bacteria and host (Gibson and Roberfroid, 1995). Due to the formation of  $\beta$ -linkages in the monomer chain, FOS are categorised as nondigestible oligosaccharides (NDOs), as such linkages cannot be hydrolysed by endogenous enzymes (Burvall et al., 1979; Oku et al., 1984). Therefore, FOS can remain available as substrates for microbial populations to utilize (Houdijk et al., 1998), and thus promote increased intestinal efficiency (Mikkelsen and Jensen, 2004).

\* Glutamine is implicated in the synthesis of proteins, as a fuel reserve for dividing cells and lymphocytes, (Krebs et al., 1980), and as a mediator in the development of intestinal epithelial cells (Windmueller and Spaeth, 1980; Wu et al., 1995). Glutamine supplementation has proven to increase intestinal performance (Yan and Qiu-Zhou, 2006), and has been found to decrease over-expression of proinflammatory genes, thus leading to a reduction in intestinal damage of rats receiving acetic acid supplementation (Fillmann et al., 2007). Glutamine has also been shown to be an essential requirement of extracellular fluid which is involved in the regulation of intentional cell volume changes, which occur as a result of cellular regulatory pathways (Ernest and Sontheimer, 2007).

\* Threonine is an essential amino acid and studies have shown that restriction of this nutrient may limit intestinal mucin synthesis and reduce gut barrier function (Hamard et al., 2007; Faure et al., 2005).

\* Laminaria hyperborea is a brown kelp or seaweed that has been found to be extremely palatable and provide increased digestible energy sources for sheep kept on the Orkney island of North Ronaldsay (Hansen et al., 2003). L. hyperborea contains higher amounts of vitamins, minerals, and proteins, when compared to conventional vegetable sources (ibid.).

\* Gastrosafe contains both calcium and magnesium which are recognised as alkaline providers and have been shown to increase intestinal mucosal integrity (Wang, 2000).

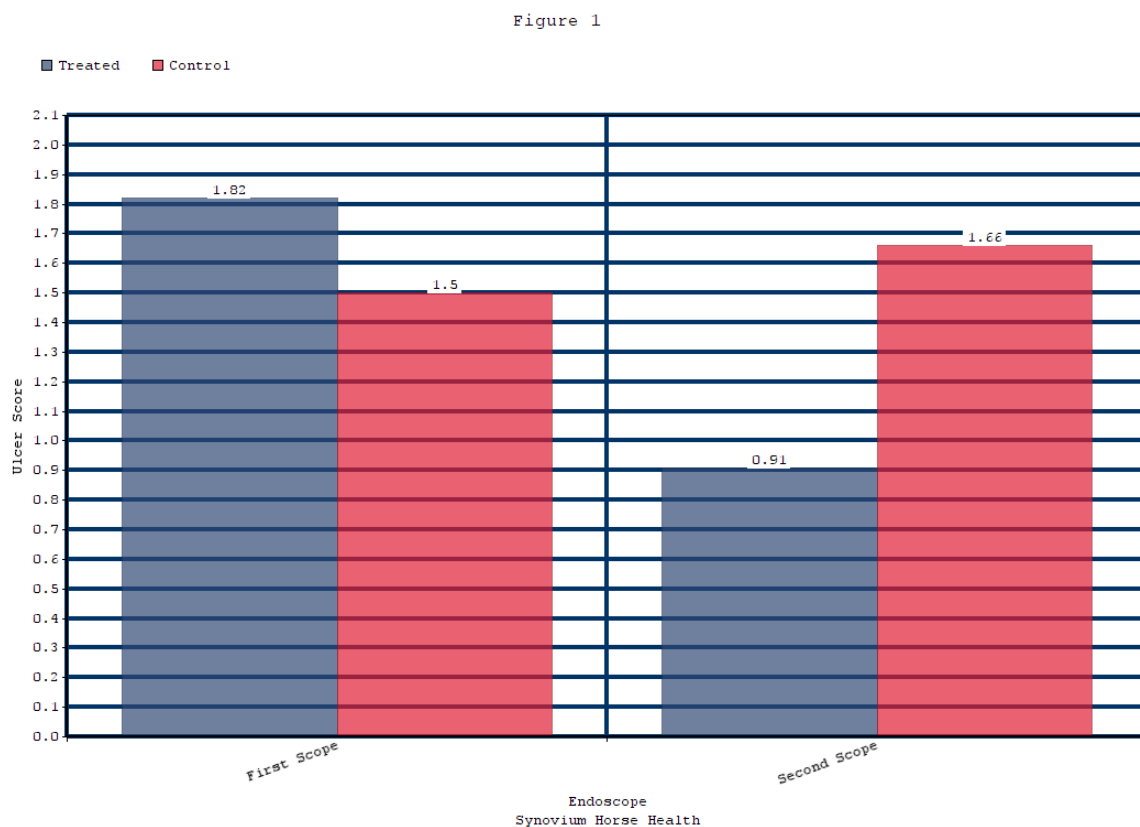
## Results

73% of supplemented horses showed an overall decrease in ulcer severity across all categories. This is in comparison to 33% of control horses showing an increase in severity, and a further 33% of control horses eliciting no change in ulcer score.

The data was tested for normality using the Kolomorgorov-Smirnov Test and found to be significant ( $P < 0.05$ ). It was therefore assumed that the data was not normally disturbed, thus a non-parametric test was used. Data was statistically analysed in SPSS using a two tailed Wilcoxon test, which allows unequal group sizes to be analysed. Overall scores (regardless of category) showed a significant reduction over the trial in supplemented horses, compared to control horses ( $p < 0.05$ ) (See figure 1). Statistical analysis on individual groups was not possible due to resultant low numbers in each, although supplemented horses showed a trend towards reduced ulcer scores.

Figure 1 shows differences in ulcer score between the first and second gastroscopy exams, in both supplemented and control groups. \* indicates significant differences between the two groups ( $P < 0.05$ ).

The average ulcer score for the supplemented group decreased from 1.82 to 0.91, whilst the average score for the control group increased from 1.5 to 1.66.



## Conclusion

This study has proven the effectiveness of Gastrosafe, as a nutritional adjunct in the management of equine gastric ulceration. A significant difference ( $P < 0.05$ ) in ulceration score was recorded after 6 weeks of supplementation, with the treated group showing significant improvement in comparison to the control group.

Due to the exceptionally high prevalence of EGUS in the thoroughbred racehorse sector and the limited availability of clinically proven nutritional feed supplements on the market, the results of this research will provide the industry with an effective nutritional tool in the management of EGUS; in conjunction, were appropriate with proton pump inhibitors such as omeprazole and H2 blockers (e.g. ranitidine, cimetidine).

## **Acknowledgments**

The Authors would like to thank Grey Abbey Veterinary Clinic, County Kildare, Ireland for performing the gastroscopic examinations.

## **References**

- Andrews F.M., Sifferman R.L., Bernard W., Hughes F.E., Holste J.E., Daurio C.P., Alva R. and Cox J.L. (1999). Efficacy of omeprazole paste in the treatment and prevention of gastric ulcers in horses. *Equine Veterinary Journal Suppl.* (29) 81-86.
- Bullimore, S.R., Corfield, A.P., Hicks, S.J., Goodall, C., and Carrington, S.D. (2001). Surface mucus in the non-glandular region of the equine stomach. *Research in Veterinary Science.* 70, 149 – 155.
- Burvall, A., Asp, N.-G. and Dahlqvist A. (1979) Oligosaccharide formation during hydrolysis of lactose with *Saccharomyces lactis* lactase (Maxilact<sup>®</sup>): Part 1. Quantitative aspects. *Food Chemistry.* 4, 243 – 250.
- Chameroy K.A., Nadeau, J.A., Bushmich, S.L., Dinger, J.E., Hoagland, T.A. and Saxton, A.M. (2006). Prevalence of non-glandular gastric ulcers in horses involved in a university riding programme. *Journal of Equine Veterinary Science.* 26, (5), 207 – 211.
- Ernest, N.J. and Sontheimer, H. (2007). Extracellular glutamine is a critical modulator for regulatory volume increase in human glioma cells. *Brain Research.* 1144, 231 – 238.
- Faure, M., Moennoz, D., Montigon, F., Mettraux, C., Breuille, D. and Balleve, O. (2005) Dietary threonine restriction specifically reduces intestinal mucin synthesis in rats, *Journal of Nutrition,* 135, (3), 486-491.
- Filipe, I.M., and Ramachandra, S. (1995). The histochemistry of intestinal mucins; Changes in disease. In: *Gastrointestinal and Oesophageal Pathology.* Ed. R Whitehead, Edinburgh. pp. 73 – 95.
- Fillmann, H., Kretzmann, N.A., San-Miguel, B., Llesuy, S., Marroni, N., GonzalezGallego, J. and Tunon, M.J. (2007). Glutamine inhibits over-expression of proinflammatory genes and down-regulates the nuclear factor kappaB pathway in an experimental model of colitis in the rat. *Toxicology.* Accepted Manuscript. Available at [www.sciencedirect.com](http://www.sciencedirect.com). Last accessed 25/04/07.
- Frape D. (1998). *Equine Nutrition and Feeding.* Blackwell Science.
- Gibson, G.R. and Roberfroid, M.B. (1995). Dietary modulation of the human colonic microbiota: introducing the concept of prebiotics. *Journal of Nutrition.* 125, 1401 –1412.
- Grossman, M.I., Kirsner, J.B. and Gillespie, J.E. (1963). Basal and histalog-stimulated Gastric secretion in control subjects and in patients with peptic ulcer or gastric cancer. *Gastroenterology* 45,14 – 26.
- Hamard, A., Mazurais, D., Boudry, G., Le Huerou-Luron, I., Seve, B. and Le Floch, N. (2007). Physiological aspects and ileal gene expression profile of early-weaned Pigslets fed a low threonine diet. *Livestock Science.* 108, 17 – 19.
- Hammond, C. J., Mason, D. K. and Watkins, K. L. (1986) Gastric ulceration in Mature Thoroughbred horses, *Equine Veterinary Journal,* 18,284-287.
- Hansen, H.R., Hector, B.L. and Feldmann, J. (2003). A qualitative and quantitative Evaluation of the seaweed diet of North Ronaldsay sheep. *Animal Feed Science and Technology.* 105, 21 – 28.
- Hartmann, A.M. and Frankeny, R.L. (2003). A preliminary investigation into the association between competition and gastric ulcer formation in non-racing performance horses. *Journal of Equine Veterinary Science.* 12, (23), 560 – 561.
- Houdijk, J.G.M., Bosch, M.W., Verstegen, M.W.A. and Berenpas, H.J., (1998). Effects of oligosaccharides on the growth performance and faecal characteristics of young growing pigs. *Animal Feed Science and Technology.* 71, 35 – 48.
- Jass, J.R. and Robertson, A.M. (1994). Colorectal mucin histochemistry in health and disease: a critical review. *Pathology International.* 44, 487 – 504.
- Johnson, B. J., Carlson, G. P., Vatistas, N. and Snyder, J. R. (1994) 'Investigation of The number and location of gastric ulcerations in horses in race training submitted To the California Racehorse Post mortem Programme', *Proceedings of the Annual Meeting of the American Association of Equine Practitioners,* 123-124.
- Jones, W.E. (2002) 'Understanding Gastric Ulcers in Horses', *Journal of Equine Veterinary Science,* 7, (22), 330.
- Kapiki, A., Costalos, C., Oikonomidou, C., Triantafyllidou, A., Loukatou, E. and Pertrohilou, V. (2007). The effect of a fructo-oligosaccharide supplemented formula on the gut flora of preterm infants. *Early Human Development.* 83, 335 – 339.
- Krebs, H.A., Baverel, G. and Lund, P., (1980). Effect of bicarbonate on glutamine metabolism. *International Journal of Biochemistry.* 12, 69 – 73.

McClure, S.R., Glickman, L.T. and Glickman, N.W. (1999). Prevalence of gastric ulcers in show horses. *Journal of the American Medical Association*. 215, 1130 – 1133.

Mikkelsen, L.L. and Jensen, B.B. (2004). Effect of fructo-oligosaccharides and transgalacto-oligosaccharides on microbial populations and microbial activity in the gastrointestinal tract of piglets post-weaning. *Animal Feed Science and Technology*. 117, 107 – 119.

Murray, M.J., Grodinsky, C., Anderson, C.W. and Radue, P.F (1989) 'Gastric ulcers in horses: A comparison of endoscopic findings in horses with and without clinical signs' *Equine Veterinary Journal, Supplement*, 7, 68-72.

Murray, M. J., and Eichron, E. S., (1996) ' Effects of intermittent feed deprivation, intermittent feed deprivation with ranitidine administration, and stall confinement with ad libitum access to hay on gastric ulceration in horses', *American Journal of Veterinary Research*, 57, 1599-1603.

Nieto J.E., Snyder, J.R., Beldomenico P., Aleman M., Kerr, J.W. and Spier, S.J. (2004). Prevalence of gastric ulcers in endurance horses – a preliminary report. *The Veterinary Journal*, 167, 33 – 37.

Oku T., Tokunaga, T. and Hosoya, N.(1984). Nondigestibility of a new sweetener, 'Neosugar', in the rat. *Journal of Nutrition*. 114, 1574 – 1581.

Quigley, E.M. and Turnberg, L.A. (1987). pH of the microclimate lining human gastric and duodenal mucosa in vivo: Studies in control subjects and in duodenal ulcer patients. *Gastroenterology* 92, 1876 – 1884.

Vatistas N.J., Snyder, J.R., Carlson, G., Johnson, B., Arthur, R.M., Thurmond, M., Zhou, H., and Lloyd, K.L. (1999). Cross-sectional study of gastric ulcers of the squamous mucosa in thoroughbred racehorses. *Equine Veterinary Journal Suppl.* 29, 34 – 39.

Wang, X. (2000). How calcium from calcium carbonate and milk benefit peptic ulcer patients. *Medical Hypotheses*. 64 (3), 432 – 433.

Windmueller, H.G. and Spaeth, A.E., (1980). Respiratory fuels and nitrogen metabolism in vivo in small intestine fed rats. Quantitative importance of glutamine, glutamate and aspartate. *Journal of Biochemistry*. 225, 107 – 112.

Wu, G., Flynn, N.E., Yan, W. and Barstow, D.G., (1995). Glutamine metabolism in chick enterocytes: absence of pyrroline-5-carboxylase synthase and citrulline synthesis. *Biochemistry Journal*. 306, 717 – 721.

Yan, L. and Qiu-Zhou, X. (2006). Dietary glutamine supplementation improves structure and function of intestine of juvenile Jian carp (*Cyprinus carpio* var. Jian). *Aquaculture*. 256, 389 – 394.