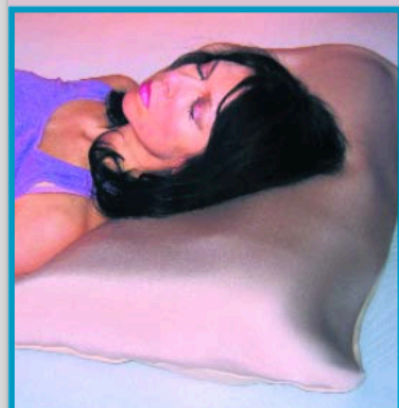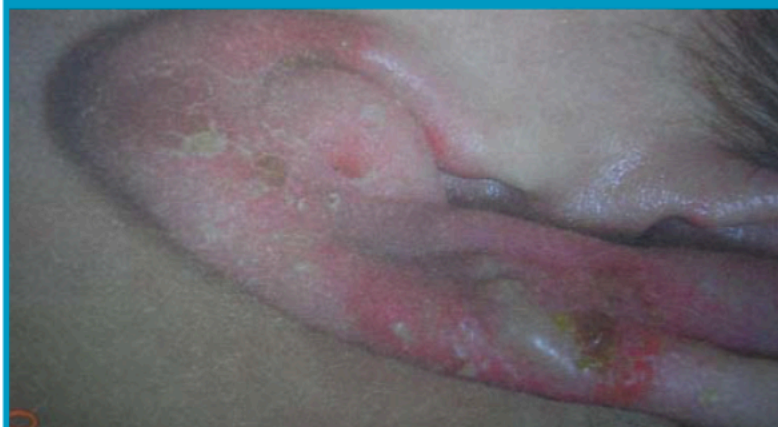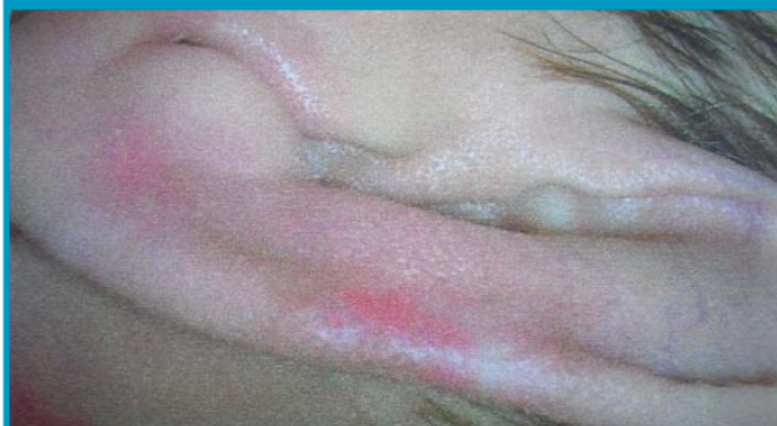


■ BY TINA HASTY, RN, CWSA

DERMASAVER PRESSURE
REDUCTION PILLOW CASE**BEFORE USING DERMASAVER PRESSURE
REDUCTION PILLOW CASE**

4/1/08

**AFTER 13 DAYS USING DERMASAVER PRESSURE
REDUCTION PILLOW CASE**

4/14/08

A 24 year old male with muscular dystrophy presented to the clinic on April 1, 2008 with a pressure wound on his left ear. The caregiver reports patient is laid on the left side due to contractures and respiratory difficulty while on his right side. The wound measurement on the left ear was 1.5cm x 0.9cm x 0.1cm. The following wound care orders were given, to cleanse ear daily with normal saline and apply thin layer of zinc oxide and to use DermaSaver Pressure Reduction Pillow Case while in bed. The patient returned on April 14, 2008 with no measurable wound and intact skin on his left ear. The skin on his left ear was pink with no drainage or reddened areas present. The care giver states he had used the DermaSaver Pressure Reduction Pillow Case for ten days and saw improvement almost immediately.